

APRIL 2024

SURGICAL GRAND ROUNDS



April 24th

Inside this issue:

<i>Surgical Grand Rounds</i>	1-6
<i>Reports From the Outfield</i>	6-7
<i>Extracurricular Productivity</i>	7
<i>Dr. Christopher Goltz</i>	8-9
<i>Dr. Larry LaGattuta Relocates to the Eternal Medical Clinic</i>	10-11
<i>Down Memory Lane</i>	12-13
<i>WSU Conferences</i>	14
<i>WSSS Dues</i>	15
<i>WSSS Members</i>	16-17

2023 WSSS OFFICERS

- President:**
Larry Narkiewicz (WSU/GS 2004/09)
- Vice-President:**
Joseph Sfera (WSUGS 1991)
- Secretary-Treasurer:**
Bruce McIntosh (WSU/GS 1989/94)
- Members-at-Large:**
Jay Dujon (WSUGS 2011)
Anita Antoniolu (WSUGS 1998)
- Resident Member:**
Paige Aiello
Molly Belisle

Dr. Sidra Bhuller, a graduating vascular surgery fellow, gave Grand Rounds on March 6, 2024, focusing on vascular access for hemodialysis. She began with an overview of vascular access options, including catheters, grafts, and conduits. The first arteriovascular graft was the Scribner shunt, designed by Belding Scribner in 1960, which was an arteriovenous shunt mechanism that was external to the patient. Since Scribner, there have been many advancements in AV shunts and grafts allowing for dialysis access on patients. Fistulas are preferably created from distal to proximal on the nondominant prior to the dominant upper extremity, but can also be created on the lower extremity. When selecting a conduit for access in lieu of adequate native vessels, PTFE grafts are used and have many different formulations which all have similar patency rates. There are also minimally invasive options for AV fistula creations, of which the Detroit Medical Center uses the WavelinQ system that utilizes magnetic catheters to create the arteriovenous fistula.



Dr. Sidra Bhuller, DO

When assessing for maturation of arteriovenous fistulas, the “Rule of 6’s” is referenced, needing a diameter of 6mm, no more than 6mm deep, 6cm of cannulation area on the vein, flow of >600cc/min, and at least 6 weeks after creation of the fistula. Failure to mature is usually due to inadequate venous dilation from small veins, sclerotic sections, side branches stealing flow, poor inflow, or stenosis. Failure to mature can be addressed based on the mechanism to attempt to preserve an otherwise patent fistula. Long-term fistula failure is most commonly caused by intimal hyperplasia. Other complications include seromas, hematomas, and infections. In the event that a patient has subclavian or internal jugular occlusions not amenable to recanalization, a HeRO graft is an option for reliable outflow dialysis access. Finally, Dr. Bhuller addressed steal syndrome, addressed when severe with the distal revascularization interval ligation (DRIL) procedure, and ischemic monomelic neuropathy which is a subtype of steal causing total hand plegia. Ischemic monomelic neuropathy must be identified and treated with fistula ligation to treat and preserve hand neurologic function.

Continue page 2

APRIL 2024

SURGICAL GRAND ROUNDS

We thank Dr. Bhuller for her thorough overview of the current updates in vascular access, and wish her well in her post-fellowship endeavors.



Dr. Anastasia Chuchulo (WSU/GS 2024) provided the Surgical Grand Rounds on 3/20/24, entitled “Pathology of the Biliary Tract: Brief Historical Overview and Discussion of Select Pathologies.” She began by discussing the normal gallbladder anatomy with a wall which should always be <4 mm in thickness. Patients with increased thickness typically have evidence of inflammation, cancer, or adenomatosis. The various diagnostic techniques that are used for abnormal biliary problems include the ultrasound, which is often the only test needed in patients with gallstones. The CT scan is helpful in identifying the total biliary tree, including the common bile duct, whereas the MRI may identify small stones that are not otherwise seen. She also discussed the syndrome of biliary dyskinesia where patients have the classic symptoms of biliary colic but do not have stones. The current guidelines for performing cholecystectomy in these patients include an ejection fraction of <35% in combination with the classic symptoms of biliary colic. Gallbladder relaxation can be achieved by cholecystokinin and glucagon.



Anastasia Chuchulo, MD

Two of the common complications of gallstones include obstructive jaundice and pancreatitis. The incidence of gallstone pancreatitis varies according to the hospital in which the patients are treated. For example, an innercity acute care hospital will have a very high incidence of pancreatitis due to alcohol, whereas a tertiary referral center, such as the Mayo Clinic, may have a very high incidence of pancreatitis due to gallstones.

Dr. Chuchulo discussed the Milwaukee Classification of Cholelithiasis, defining the three types based upon symptoms and clinical findings. Patients with complicated biliary tract disease may be candidates for ERCP whereas patients with sphincter of Oddi dysfunction may be candidates for endoscopic sphincterotomy or, during laparoscopic cholecystectomy, a forward balloon dilation of the sphincter.

One of the feared complications of laparoscopic cholecystectomy is inadvertent ductal injury which may lead to severe complications and even death. The incidence of bile duct injury has decreased markedly and is now <1%. This represents the emphasis that many writers have

Continue page 3



APRIL 2024

SURGICAL GRAND ROUNDS

placed on identifying the normal anatomy and anticipating abnormal anatomy. Often patients who have a routine laparoscopic cholecystectomy do well on the day of surgery but return shortly thereafter with right upper quadrant pain and tenderness. When ultrasound examination demonstrates an infrahepatic fluid collection, the treatment should be percutaneous drainage followed by ERCP once the patient has improved. The principle that is followed in this sequence is treatment of the problem first and correction of the cause second. The ERCP may identify different degrees of severity of extrahepatic biliary injury, including a tiny leak from the cystic duct which can be treated by an endoscopically placed stent. A more severe injury depends on whether the duct is partially divided or completely divided and also whether the division occurs distal to the cystic duct entrance, at the cystic duct entrance, in the common bile duct below the bifurcation of the right and left bile ducts, or involve the proximal common bile duct at the junction of the right or left or both hepatic ducts. When the injury is identified during operation, the surgeon should call for help and plan to do an open laparotomy with definitive repair of the injury, often with a Roux-en-Y hepaticojejunostomy or if the injury is beyond the technical skill of the surgeon, placement of appropriate drains with plans to come back at a later date.

Dr. Chuchulo presented the history of gallbladder stones which were first described in 2000 B.C. More recently, in the 17th century, Glisson described the gallbladder anatomy, including the gallbladder capsule which bears his name. In the early portion of the 18th century, Pettis described gallbladder cancer, and the first cholecystectomy was reported in the late 19th century by Bolb who operated on a patient with a suspected ovarian cyst and found an acute gallbladder packed with stones that he successfully removed. Later in the early 19th century, Langerback performed the first planned cholecystectomy in a 43-year-old woman who did well. The famous triangle of Calot was described in 1890, and the right upper quadrant incision for open cholecystectomy was described by Kocher in 1992. Courvoisier described his famous sign in 1900. A patient with jaundice who had a palpable right upper quadrant mass often had cancer, whereas a patient with jaundice with no right upper quadrant mass likely had gallstones because of the repeated bouts of cholecystitis caused scarification of the gallbladder which would not become markedly distended.

Other important authors in the area of biliary disease included Mirizzi, who described the jaundice associated with a distal cystic duct stone which was compressing the common duct. The image study that we now call the HIDA test for cholecystitis was described by Warren Cole in the 1950's, and ERCP was introduced in the 1980's. Mube in 1985 first introduced the laparoscopic technique for cholecystectomy and was somewhat criticized by the statement, "Small brain – small surgery." Within the next ten years, lap chole became the most common

Continue page 4

APRIL 2024

SURGICAL GRAND ROUNDS

technique for cholecystectomy, representing over 80% of the cholecystectomies and now represents well over 90% of the cholecystectomies.

Dr. Chuchulo identified many of the anatomic anomalies, including cystic artery anomalies, which may come off of the right hepatic artery and occasionally from the left hepatic artery. She also described how sometimes the cystic artery will be long and wandering and end up going superiorly along the lateral surface of the gallbladder, whereas other times it will be very short, creating the potential for injury to the right hepatic artery. There may also be a high trifurcation of the right hepatic artery and cystic artery. When one is confused about the anatomy and identifies the right hepatic duct as the cystic duct, the likelihood of identifying the right hepatic artery as the cystic artery is very high, and in some experiences, division of the right hepatic artery occurs in almost 50% of patients who have inappropriate division of the right hepatic duct or the common hepatic duct. This should not cause liver necrosis unless there is also an injury to the right branch of the portal vein.

Other anomalies that were discussed include the Phrygian cap where the upper part of the gallbladder has a circumferential indentation; the double gallbladder, which occurs less than 1% of the time; or a diverticulum gallbladder. Absence of a gallbladder is a very rare anomaly.

Common bile duct stones present an unusual problem with gallbladder disease. These have been removed by lithotripsy, but the complications include portions of a stone blocking the sphincter of Oddi leading to pancreatitis. She described the clearance of common bile duct stones at the time of laparoscopic cholecystectomy by a balloon flush and a balloon dilation of the sphincter. Other techniques include laparoscopic common bile duct exploration and passage of stone removers. Alternatively, one may do a common duct exploration through the cystic duct followed by balloon dilation and flushing. Patients needing reconstruction of the bile duct after complete severance are candidates for a Roux-en-Y hepaticojejunostomy.

Her excellent and thorough presentation was followed by a good question-and-answer session.



The Surgical Grand Rounds for Wednesday, 3/27/24 was presented by Dr. Yuchen (Kelly) Zhang, a senior graduating resident in Surgical Critical Care, and was entitled, "Time to Say Goodbye: The Quest of Dying with Dignity." She was introduced by Dr. Steve Tennenberg who

Continue page 5



APRIL 2024

SURGICAL GRAND ROUNDS

is the Director for the Surgical Critical Care Fellowship. Dr. Zhang identified the objectives of her presentation which dealt with end-of-life care, the definition of a good death, and the things that should be considered when dealing with a dying patient. She went through some of the historical aspects, including a definition by Dr. Montaigne in the 1570's about dying in old age without pain is a blessing. Dame Saunders from London emphasized the importance of palliative care in 1667, and this led to the hospice movement and the importance of identifying a patient's right to say, "You are you," and die in a manner which is compatible with the patient's wishes.



Dr. Yuchen Kelly Zhang

Greater emphasis was made in the 1970's in the USA, and this led to serious discussions at the Morbidity and Mortality conferences. The World Health Organization in 1990 emphasized life limiting procedures in patients who had no probability of surviving, whereas the renowned Elisabeth Kubler Ross defined the stages of death, including Denial, Anger, Bargaining, Depression, and finally Acceptance. The Institute of Medicine in 1997 began to report on statistics regarding dying, and this helped place more emphasis on the total process. The things that must be considered in this situation include the diagnosis, the prognosis, and the patient's family. Practical considerations include legalities, particularly those that deal with financial aspects and religious beliefs. Finally, control of pain is an important part of transition from life to death.



Dr. Steven Tennenberg

In the 19th century, most people would die at home at an average age of about 50 years. By 2000, the process of death was more protracted and often associated with co-morbidities such as COPD and organ failure with the result that the death process was slow. The average age by 2021 is 74 years, and since the beginning of the 19th century, more and more people are dying in hospitals or nursing homes or extended care facilities.

The importance of quality of life in dying was emphasized, and a cultural acceptance of dying with comfort has become more popular. The definition of death has also undergone changes, particularly as it relates to the definition of brain death in patients who then may become candidates for organ transplantation. Dr. Zhang emphasized the importance of having an Advanced Directive and to have someone defined as having the Power of Attorney in order to deal with some of the legalities as one progresses towards death. This can result in serious discussions about advanced care planning in patients who have reached that point in their journey from life to death.

Continue page 6

APRIL 2024

SURGICAL GRAND ROUNDS

The things that deal with extended care and assisted dying have become part of the Internal Medicine Boards in 2016 and the Physical Medicine and Rehabilitation Boards in 2015. Similar items have been added to the Board examinations in Pediatrics, Surgery, and Anesthesia.

There was an active discussion following her presentation. Part of the discussion related to the activities of Dr. Jack Kevorkian who provided assistance in dying in such a way that he enabled a patient to turn on the intravenous infusion which would bring about death promptly. Dr. Kevorkian was convicted of murder and went to prison. The actions that he propagated, namely assisted suicide, have been enacted into laws in many states in the country.



REPORTS FROM THE OUTFIELD

Dr. Luis Gabe Camero, MD (WSUGS/TS 1977/79) finished his Thoracic Surgery residency in 1979 under the guidance of Dr. Robert F. Wilson and his Pediatric Cardiac Surgery Fellowship in 1980 under the guidance of Dr. Arciniegas. Following his training, he continued to work in southeast Michigan and more specifically spent most of his time working at St. John Hospital on the east side. He developed a very busy practice up until 2019 when he decided he wanted to enjoy the southern environment and moved to Jacksonville, Florida for his retirement. Dr. Camero sends his best wishes to the members of the WSSS and can be reached at colombiacamero@hotmail.com.



Dr. Luis G. Camero




Continue page 7

APRIL 2024



REPORTS FROM THE OUTFIELD

Dr. Faraz Ali Khan finished his general surgery residency at WSU in 2016 and below is a summary of what's been happening in his life since his graduation.



Dr. Faraz Ali Khan and his bride, Dr. Asra Khan

Dear Dr. Lucas,

I hope you and Dr. Ledgerwood are doing well. As always I enjoyed reading the department of surgery monthly report.

We moved to the SF Bay Area last year after 5 years on faculty at the Loma Linda University in Southern California. I work primarily at Lucile Packard Children's Hospital and on faculty in the Department of Surgery at Stanford.

Asra works for Kaiser Permanente in South Bay (San Jose). We have two boys now, they are 3 and 1. The transition has been great, the job has been very fulfilling. There is a lot of very complex pathology that I have been fortunate enough to manage. Asra really likes her practice as well, she does mostly complex Craniofacial and is typically booked out for months. The boys keep us busy for days we are off, they love exploring outdoors. Hope to see you here in San Francisco for the clinical congress later this year.

Just wanted to point out that the 49ers play at Levi stadium here in Santa Clara near San Jose (South SF Bay).



EXTRA-CURRICULAR PRODUCTIVITY



Dr. Anastasia Stevens-Chase

Dr. Anastasia Stevens-Chase (WSUGS/MIS 2020/22) and her husband, Scott Chase, welcomed their new baby girl, Sloane Liale Chase (WSU/GS 2058). She weighed 7 lbs, 2 oz and was born at 21 inches tall. She is providing the two of them wonderful joy and, as Anastasia says, some sleepless nights. The green pajamas represent her birth near St. Patrick's Day (March 17).



Ms. Sloane Liale Chase

All of the WSSS members wish the three of them a wonderful co-existence for the next many years.




APRIL 2024

Dr. Christopher Goltz, MD

Dr. Christopher Goltz (WSU/GS 2013) is a busy general vascular surgeon working in Flint, Michigan. The following is an update on some of his exciting activities.

Dear Dr. Lucas,

I must first apologize as I have taken my time in writing back to you since we discussed cases at the Detroit Trauma Symposium. Knowing that it is better to be late than never - I have written below some of my experiences with traumatic vascular injury.



Dr. Christopher Goltz

I am currently practicing in Flint and credit my experiences in training in Detroit with my comfort level in treating trauma patients. For some time during my first several years of my practice I was known as the trauma guy as all of the injuries needing arterial reconstruction seemed to come in while I was on call. Fortunately for my sanity I have had this black cloud move from over my head and the cases have since been spread more evenly amongst my partners. We have a good relationship with the trauma surgeons at Hurley hospital which tends to have the majority of the penetrating trauma in our region. The trauma system set up there works well, and despite the economic limitations that are inherent to a county hospital excellent care is provided.

One morning I was called in by one of my junior partners to help with a left subclavian injury. Fortunately one of the trauma surgeons was facile and able to place a clamp on the origin of the left subclavian in the chest. When I arrived the tissues in the affected area were shredded and it was difficult to discern any named structures. In order to facilitate exposure the clavicle was resected, and we were able to define the distal subclavian. From this point the left carotid was not involved in the injury and a carotid to subclavian bypass was performed with good result. We did find a large section of clot in the subclavian that was removed with passage of embolectomy catheters.

I was recently asked to assist with a patient who was bleeding from an exposure in the pelvis. The patient had a retroperitoneal mass likely consistent with lymphoma but attempts at percutaneous biopsy had been non diagnostic. A robotic approach to biopsy was therefore attempted. On entry the surgeon noted dense inflammatory tissue that made it impossible to define planes. Several biopsies were taken but none had adequate pathology for diagnosis, and as deeper sections were obtained the external iliac artery was injured. I was called in at this point and after removing the troublesome robot and

Continue page 9

APRIL 2024

Dr. Christopher Goltz, MD, cont.

opening was able to gain control of the common and proximal external iliac. Suture ligation of the injured segment was performed and we did a common iliac to common femoral bypass as the external was encased in tumor.

I operated on a young man with a gunshot wound to the groin. CTA demonstrated a large pseudoaneurysm. On opening the groin the superficial femoral had been transected at its origin. Additionally the common femoral vein had a large laceration. We used a segment of contralateral saphenous vein for repair of the arterial injury. As the injury was to the common femoral vein we felt that repair should be attempted. I first did a patch angioplasty repair however noted that this significantly narrowed the vessel, and subsequently a short interposition PTFE bypass was done. The patient generally did well, and was discharged. He did present several weeks later with leg swelling and the vein repair was noted to be occluded but he declined attempts at repair of this as his symptoms were not severe.

One of the most frustrating traumatic injuries that I have worked on was a 45 year old male who was dropped off at the ER of a non-trauma center hospital for a gunshot wound to the leg. The bullet had traversed between the tibia and fibula, and in avoiding all of the bones had managed to injure all three tibial vessels. We did a popliteal to posterior tibial bypass with a segment of contralateral saphenous vein. We decided to do a completion angiogram which showed no flow past the end of the bypass. I felt a technical error was most likely and the bypass was re done, embolectomy catheters and dilators were passed, vasodilators were given, and after the revision was done there was still no flow in the bypass. We then revised the distal to a more distal segment of the artery. Final angiogram was done that again showed no flow. I was frustrated at this point and given the multiple revisions felt that there was nothing more that could be done. We closed and in recovery the patient was examined and had a palpable pulse, and despite extensive efforts to resolve it arterial spasm was the culprit, not any technical error.

Finally I wanted to note how much I enjoyed the Trauma Symposium this year. The presentations reinforced to me the basis of trauma care to the care of so many other patients. It seems clear to me that although we have some differences in training and daily practice going back to the basics is so important for all of us. Thanks for the invitation to write.

Best wishes

Christopher Goltz, MD, FACS (WSUGS 2013)



The Goltz family at the Badlands in South Dakota last Summer. (Left to right) Dr. Christopher Goltz, their son, Eli (age 10), their son, Gabriel (age 12), and Dr. Goltz's bride, Natalie



APRIL 2024

RURAL GENERAL SURGEON RELOCATES TO THE ETERNAL MEDICAL CLINIC

Dr. Laurence (Larry) Andrew LaGattuta was born in Antwerp, Belgium to American parents. They managed to take the last boat out of Belgium at the beginning of World War II and settled in New Jersey. The family moved to Mexico City when he was in high school, and he learned to master his Mexican accent. He and his good high school friend, Ron Peterson, decided to become physicians. Following high school, Larry served in the U.S. Army during the Korean War where he was confined to desk work in England and then returned to the States to finish his undergraduate education at Rutgers and his medical training at Boston University.



Dr. Larry LaGattuta and his bride, Dottie, and their 4 children, Suzanne, David, Diana, and Daniel

Following his internship, he began a surgical residency at the Wayne State University and the Detroit Receiving Hospital (DRH) where he met his future wife, Dottie, who was a nurse in the DRH Emergency Room. They married in 1964, and following the completion of his residency in 1967, they moved to Allegan, Michigan. This move was prompted by their desire to raise their children far away from the tensions seen in the big city. They had recently been exposed to the Detroit Riot which occurred in the summer of 1967 and was the worst riot in the United States during that tumultuous year.

Working with his good friend, Dr. Harry Schneiter, they formed the Allegan Medical Clinic in order to bring primary care services to the residents of Allegan and obviate the need for them to get treated in larger nearby cities. During these early years, Larry was a true general surgeon who performed all of the gastrointestinal procedures, many urological procedures, straightforward vascular procedures, orthopedic operations, and obstetrics/gynecology. During his residency years, he and the other general surgical residents were performing all of these operations as part of their general surgical training. Because the team there performed all types of specialty operations, this provided the residents of Allegan the opportunity to get their total care within their own community. Dr. LaGattuta also established the Intensive Care Unit at the Allegan General Hospital and retained his cognitive skills in the care of critically ill patients who no longer had to be transferred to larger hospital in Kalamazoo or Holland, Michigan. Led by his example, he was able to attract many colleagues to this hospital so that the vast majority of patients within their community were treated at the Allegan Medical Clinic. Because he was the only surgeon within a 20-mile radius, he always carried his pager and was essentially on call every night. Often his family had no idea where he was when he didn't show up for breakfast and later learned that he was doing an emergency C-section or appendectomy. Because he worked full-time in a small community, most of the patients who entered into the Allegan Medical Clinic were known by Larry because they were essentially all his neighbors.

Continue page 11



APRIL 2024

RURAL GENERAL SURGEON RELOCATES TO THE ETERNAL MEDICAL CLINIC, cont..

During these years, he was able to fulfill his inner need to be involved in teaching, and he received students who rotated with him from the University of Michigan medical school and the Western Michigan University P.A. program, and his group grew to eventually include three surgeons, two internists, eight family practitioners, a pediatrician, and a handful of P.A.'s. He had a very successful career and was recognized for his contributions to the community, so much so that the city of Allegan named two of their streets "LaGattuta Lane" and "Schneiter Blvd" because of the contributions these two physicians had made to healthcare in this small community.

While still very busy in his practice, he purchased 18 acres of what appeared to be swamp land by the Kalamazoo River on Monroe Road in Allegan. He spent his free time moving earth in order to develop a protected farmland where he was able to communicate with the occasional woodchuck and raccoon. He built himself a barn and with no experience, began to raise chickens and cattle. Not wanting to offend his children who might become too attached to the steers, he named the two steers "Burger Chef" and "McDonald's." Larry also had a need to be involved in many activities; for example, he revitalized the family cabin on Bass Lake in Traverse City. This was the original cabin that was built by Dottie's grandfather in the 1940's. Larry increased the size, built a dock, and added indoor plumbing and electricity so that the "cabin" became a cottage and was the location for many family gatherings, peaceful fly-fishing escapes, and ultimately his favorite place when the climate was right.

Following his retirement from active practice in 2008, they moved to a condo in Allegan and spent some time in Florida trying to improve their golf scores. Larry continued to serve the Allegan Medical Center where he served as a trustee on the hospital board while Dottie had the job of supervising him and a handful of grandchildren. When he first retired, he often had dreams that he was still in the operating room, but that gradually changed as he got more involved in so many other activities.

Larry was also known for his sense of humor which was appreciated by his fellow residents, faculty, and patients. Following his retirement, he would often speak with foreign accents to his friends and colleagues or to any poor telemarketer who happened to call the LaGattuta land line.


Larry relocated to that great operating room in the sky at age 93 on October 13, 2023. He is survived by his wife Dottie, his four children, including Suzanne who is married to Jim, David who is married to Pam, Diana, and Daniel who is married to Evelina; his grandchildren Carrie, Amanda, Erica, Kyle, Joseph, Alaina, and Sophia; and great grandchildren George, Cian, Juniper, and Aurora. Whether in life or death, whenever one thinks of Larry LaGattuta, a smile comes to one's face.



EXCERPTS FROM THE LOG BOOK DOWN MEMORY LANE

3/2/72 - Staff: Dr. Threlked; Chief Resident: Dr. A. Ledgerwood

1. CH: 48-yo with right arm crushed between two cars with fracture distal one-third right humerus and absent radial pulse. Right brachial arteriogram showed occlusion right brachial artery at fracture site. Artery was explored after Ortho put Rush rod down humerus; found transection biceps and brachial artery and vein transected. All nerves intact. Vein ligated. Artery repaired with end-to-end anastomosis.
2. JB: 31-yo with stab right anterior eighth intercostal space and right flank, felt to be penetrating when probed. Exploratory laparotomy showed neither wound penetrated.



Dr. Anna Ledgerwood

3/3/72 - Staff: Dr. J. Kirkpatrick

1. GK: 62-yo with generalized peritonitis. Laparotomy showed ruptured left pyelonephrotic kidney treated with drainage.
2. PB: Stab left neck, right chest, and abdomen. Exploration of neck and ligation small arterial bleeders.
3. HH: 24-yo law student with multiple GSWs, hypotensive, and arrested. Left thoracotomy and heart beating but aorta empty. Aorta cross clamped. Taken to O.R.; laparotomy showed perforation IVC, SMA, and arteries in the mesentery. Patient expired in O.R.
4. TR: GSW abdomen and hypotension in 24-yo male. Exploratory laparotomy showed perforated small bowel x7, transverse colon, sigmoid colon, right lobe liver, mesentery small bowel. Treated with small bowel resection x2, suture liver, closure sigmoid colon, transverse colostomy, mucous fistula.
5. WW: I&D huge perirectal abscess.

3/4/72 - Staff: Dr. Norman Thoms

1. CL: Replaced exteriorized repaired colon into the peritoneal cavity.
2. CB: Dressing change and debridement left thigh.
3. JD101: GSW abdomen. Exploratory laparotomy, splenectomy, distal pancreatectomy, left nephrectomy, and closure holes left diaphragm.
4. MW: I&D perirectal abscess.
5. AJ: Stab left chest with multiple stabs. Left thoracotomy and ligation intercostal artery.

3/5/72 - Staff: Dr. Y. Silva

1. GH: Acute appendicitis, treated with appendectomy. Path report said normal appendix.
2. EL: 15-yo with acute appendicitis, treated with appendectomy.

Continue page 13



"EXCERPTS FROM LOG BOOK" - DOWN MEMORY LANE, cont...

3/6/72 - Staff: Dr. Birks

1. CB: Debridement SGW and dressing change.
2. WA: 62-yo with small bowel obstruction due to adhesive band from mesentery small bowel diverticulum to sigmoid colon. Treated with lysis of adhesions and exploratory laparotomy.
3. LP: GSW abdomen in 21-yo with perforation cecum at the ileocecal valve and internal iliac vein, fracture ileum, and two holes small bowel. Treated with laparotomy, right colectomy with ileal transverse colostomy and anastomosis with exteriorization repair. There was also closure small bowel and ligation iliac vein.
4. JW: 21-yo with GSW abdomen, two holes urinary bladder, and two holes rectum. Treated with closure anterior hole rectum and bladder holes with placement suprapubic tube, sigmoid loop colostomy, and presacral drains.

3/7/72 - Staff: Dr. Zwi Steiger

1. EW: Small bowel fistula from previous laparotomy, treated with vagotomy and antrectomy and small bowel resection.
2. JD112: Multiple stab wounds treated with ligation femoral vein, repair of femoral artery, left thoracotomy, and internal cardiac massage.
3. LP: Prolapsed exteriorized colon anastomosis, treated with repair of fascial bridge.
4. JD101: Previous GSW with distal pancreatectomy and splenectomy. Treated with exploratory laparotomy, evacuation of clots, ligation of vessel of greater curvature of stomach, small bowel decompression, and tracheostomy.
5. SB: 24-yo with appendectomy and normal appendix, noted to have inflamed gallbladder, treated with cholecystectomy.
6. JD: I&D abscess right knee with debridement.

3/8/72 - Staff: Dr. Joe Bassett

1. WG: Appendectomy for acute perforated appendicitis.
2. AG: Debridement and closure large wounds thigh from dog bite.
3. HH: GSW left chest x2 treated with thoracotomy, internal massage, extensive bleeding from fractured ribs and intercostal vessels. Patient expired in O.R. and was one of four Sheriff Deputies shot by the Stress Unit.
4. AJ: 29-yo with injury left index finger, treated with debridement and closure of amputated tip.
5. AH: 33-yo in MVC with fracture of left 5-10 ribs, flail chest, and fractured pelvis with hematuria, treated with tracheostomy.
6. AC: SGW left shoulder with fractured scapula, treated with debridement.
7. JH: 33-yo with acute abdomen. Exploratory laparotomy showed pelvic inflammatory disease.



WSU MONTLY CONFERENCES 2024

Death & Complications Conference
Every Wednesday from 7-8



Didactic Lectures — 8 am
Kresge Auditorium

*The weblink for the New WebEx Room:
<https://davidedelman.my.webex.com/meet/dedelman>*

Wednesday, April 3

Death & Complications Conference

Disparities in Hepato-Pancreato-Biliary Malignancies: Incidence, Management, and Outcomes

Eliza Beal, MD

Assistant Professor of Oncology and Surgery
Karmanos Cancer Institute/Wayne State University

Wednesday, April 10

Death & Complications Conference

Amanda Johnston, DO

Graduating Surgical Critical Care Resident
DMC/WSU School of Medicine

Wednesday, April 17

Death & Complications Conference

Alison Karadjoff, DO

Graduating Surgery Resident, DMC/WSU School of Medicine

Wednesday, April 24

Death & Complications Conference

Jock Thacker, MD

Graduating Surgery Resident, DMC/WSU School of Medicine

**RESGE AUDITORIUM – SECOND FLOOR WEBBER BLDG
HARPER UNIVERSITY HOSPITAL, 3990 JOHN R.
7:00 Conference: Approved for 1 Hour – Category 1 Credit
8:00 Conference: Approved for 1 Hour – Category 1 Credit
For further information call (313) 993-2745**

The Wayne State University School of Medicine is accredited by the Accreditation Council for Continuing Medical Education to provide continuing medical education for physicians. The Wayne State University School of Medicine designates this live activity for a maximum of 2 hours *AMA PRA Category 1 Credit(s)*[™]. Physicians should claim only the credit commensurate with the extent of their participation in the activity.[†]

EVALUATIONS

Surgical Death and Complications Rounds #2024321125, Jan-April 2024 CME Reflective Evaluation:

<https://www.surveymonkey.com/r/MJMNVV>

Surgery Grand Rounds #2024321064, Jan-April 2024 CME Reflective Evaluation:

<https://www.surveymonkey.com/r/MJW12XF>



**Wayne State Surgical Society
2024 Donation**

Name: _____

Address: _____

City/State/Zip: _____

Service Description	Amount
---------------------	--------

2024 Dues Payment _____	\$200	_____
-------------------------	-------	-------

My contribution for "An Operation A Year for WSU" _____		_____
---	--	-------

*Charter Life Member _____	\$1000	_____
----------------------------	--------	-------

Total Paid _____

Payment by Credit Card

Include your credit card information below and mail it or fax it to 313-993-7729.

Credit Card Number: _____

Type: MasterCard Visa Expiration Date: (MM/YY) _____ Code _____

Name as it appears on card: _____

Signature: _____

Billing address of card (if different from above):

Street Address _____

City _____ State _____ Zip Code _____

*I want to commit to becoming a charter life member with payment of \$1000 per year for the next ten (10) years.

Send check made payable to **Wayne State Surgical Society** to:

Charles Lucas, MD
Department of Surgery
Detroit Receiving Hospital, Room 2V
4201 St. Antoine Street
Detroit, Michigan 48201

MARK YOUR CALENDARS

Michigan Chapter of the American College of Surgeons

May 1-3, 2024

*Radisson Plaza Hotel
Kalamazoo, Michigan*

*Midwest Surgical Association Annual Meeting
August 4-6, 2024*

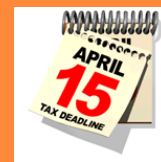*Grand Hotel
Mackinac Island, Michigan*

*88th Annual Meeting of the American Association for
the Surgery of Trauma/ Clinical Congress of Acute
Care Surgery*

*September 11-24, 2024
Las Vegas, Nevada*

*American College of Surgeons Clinical Congress
Annual Meeting*

*October 19-22, 2024
San Francisco, California*



**Please Update Your
Information**

The WSUSOM Department of Surgery wants to stay in touch. Please email Charles Lucas at clucas@med.wayne.edu to update your contact information.



Missing Emails

Over the years the WSU Department of Surgery has lost touch with many of its alumni. If you know the email, address, or phone number of the following WSU Department of Surgery Residency Program graduates please email us at clucas@med.wayne.edu with their information so that we can get them on the distribution list for the WSU Department of Surgery Alumni Monthly Email Report.

Mohammad Ali (1973)

David B. Allen (1992)

Tayful R. Ayalp (1979)

Juan C. Aletta (1982)

Kuan-Cheng Chen (1976)

Elizabeth Colaiuta (2001)

Fernando I. Colon (1991)

David Davis (1984)

Teoman Demir (1996)

Judy A. Emanuele (1997)

Lawrence J. Goldstein (1993)

Raghuram Gorti (2002)

Karin Haji (1973)

Morteza Hariri (1970)

Harrison, Vincent L. (2009)

Abdul A. Hassan (1971)

Rose L. Jumah (2006)

R. Kambhampati (2003)

Aftab Khan (1973)

Samuel D. Lyons (1988)

Dean R. Marson (1997)

Syed A. Mehmood (2007)

Toby Meltzer (1987)

Roberto Mendez (1997)

Mark D. Morasch (1998)

Daniel J. Olson (1993)

David Packer (1998)

Y. Park (1972)

Bhavik G. Patel (2004)

Ami Raafat (1998)

Kevin Radecki (2001)

Sudarshan R. Reddy (1984)

Renato G. Ruggiero (1994)

Parvid Sadjadi (1971)

Samson P. Samuel (1996)

Knavery D. Scaff (2003)

Steven C. Schueller (1974)

Anand G. Shah (2005)

Anil Shetty (2008)

Chanderdeep Singh (2002)

David G. Tse (1997)

Christopher N. Vashi (2007)

Larry A. Wolk (1984)

Peter Y. Wong (2002)

Shane Yamane (2005)

Chungie Yang (2005)

Hossein A. Yazdy (1970)

Lawrence S. Zachary (1985)

Wayne State Surgical Society

The Wayne State Surgical Society (WSSS) was established during the tenure of Dr. Alexander J. Walt as the Chairman of the Department of Surgery. WSSS was designed to create closer contact between the current faculty and residents with the former resident members in order to create a living family of all of the WSU Department of Surgery. The WSSS also supports department activities. Charter/Life Membership in the WSSS is attained by a donation of \$1,000 per year for ten years or \$10,000 prior to ten years. Annual membership is attained by a donation of \$200 per year. WSSS supports a visiting lecturer each fall and co-sponsors the annual reception of the department at the annual meeting of the American College of Surgeons. Dr. Scott Davidson (WSU/GS 1990/96) passed the baton of presidency to Dr. Larry Narkiewicz (WSU/GS 2004/09) at the WSSS gathering during the American College of Surgeons meeting in October 2022. Members of the WSSS are listed on the next page. Dr. Narkiewicz continues in the hope that all former residents will become lifetime members of the WSSS and participate in the annual sponsored lectureship and the annual reunion at the American College of Surgeons meeting.



Members of the Wayne State Surgical Society Charter Life Members

Ahn, Dean	Clink, Douglas	Gerrick Stanley	Lucas, Charles E.	Ramnauth, Subhash	vonBerg, Vollrad J. (Deceased)
Albaran, Renato G	Chmielewski, Gary W.	Grifka Thomas J. (Deceased 2022)	Malian, Michael S.	Rector, Frederick	Washington, Bruce C.
Allaben, Robert D. (Deceased)	Colon, Fernando I.	Gutowski, Tomasz D.	Marquez, JoFrances	Rose, Alexander	Walt, Alexander (Deceased)
Ames, Elliot L.	Conway, William Charles	Herman, Mark A.	Martin, Donald J., Jr.	Rosenberg, Jerry C.	Weaver, Donald
Amirikia, Kathryn C.	Davidson, Scott B.	Hinshaw, Keith A.	Maxwell, Nicholas	Sankaran, Surya	Whittle, Thomas J.
Anslow, Richard D.	Dente, Christopher	Holmes, Robert J.	McGuire, Timothy	Sarin, Susan	Williams, Mallory
Antonioli, Anita L.	Dujon, Jay	Huebl, Herbert C.	McIntosh, Bruce	Sferra, Joseph	Wills, Hale
Auer, George	Edelman, David A.	Johnson, Jeffrey R.	Missavage, Anne	Shapiro, Brian	Wilson, Robert F.
Babel, James B.	Engwall, Sandra	Johnson, Pamela D.	Montenegro, Carlos E.	Silbergleit, Allen (Deceased)	Wood, Michael H.
Bassett, Joseph (Deceased)	Francis, Wesley	Kline, Gary	Narkiewicz, Lawrence	Smith, Daniel	Zahriya, Karim
Baylor, Alfred	Flynn, Lisa M.	Kovalik, Simon G.	Nicholas, Jeffrey M.	Smith, Randall W.	
Bouwman, David	Fromm, Stefan H.	Lange, William (Deceased)	Novakovic, Rachel L.	Stassinopoulos, Jerry	
Bradley, Jennifer	Fromm, David G	Lau, David	Perrone, Erin	Sullivan, Daniel M.	
Busuito, Christina	Galpin, Peter A.	Ledgerwood, Anna M.	Porter, Donald	Sugawa, Choichi	
Crocco, William C.	Gayer, Christopher P.	Lim, John J.	Prendergast, Michael	Tuma, Martin	



Earth Day
April 15th

Members of the Wayne State Surgical Society—2023-24 Dues

Alpendre, Cristiano V.	Goltz, Christopher J.	Marquez, JoFrances	Siegel, Thomas S.
Bambach, Gregory A.	Gutowski, Tomasz	Martin, Jonathon	Tarras, Samantha
Carlin, Arthur	Hall, Jeffrey	McGee, Jessica D.	Taylor, Michael G.
Chmielewski, Gary	Hollenbeck, Andrew	Mostafa, Gamal	Tennenberg, Steven
Dawson, Konrad L.	Joseph, Anthony	Nevonen, Marvin G.	Thoms, Norman W.
Dolman, Heather	Klein, Michael D.	Paley, Daniel S.	Vasquez, Julio
Dulchavsky, Scott A.	Kline, Gary	Park, David	Ziegler, Daniel W.
Fernandez-Gerena, Jose	Kosir, Mary Ann	Porterfield, Lee	
Field, Erin	Lloyd, Larry	Shanti, Christina	




Arbor Day
April 26th

Operation-A-Year January 1—December 31, 2024



The WSU department of Surgery has instituted a new group of alumni who are remembering their training by donating the proceeds of one operation a year to the department. Those who join this new effort will be recognized herein as annual contributors. We hope that all of you will remember the department by donating one operation, regardless of difficulty or reimbursement, to the department to help train your replacements. Please send you donation to the Wayne State Surgical Society in care of Dr. Charles E. Lucas at Detroit Receiving Hospital, 4201 St. Antoine Street (Room 2V), Detroit, MI, 48201.

Albaran, Renato G.	Dittinbir, Mark	Holmes, Robert J.	McGuire, Timothy	Sullivan, Daniel M.
Antonioli, Anita L.	Engwall, Sandra	Johnson, Jeffrey R.	McIntosh, Bruce	Wood, Michael H.
Bambach, Gregory A.	Fernandez-Gerena, Jose	Johnson, Pamela D.	Porter, Donald	Ziegler, Daniel
Bradley, Jennifer	Gutowski, Tomasz	Joseph, Anthony	Prendergast, Michael	
Busuito, Christina	Gayer, Christopher P.	Lim, John J.	Siegel, Thomas S.	
Chmielewski, Gary W.	Herman, Mark A.	Malian, Michael	Smith, Daniel	
Dente, Christopher	Hinshaw, Keith A.	Marquez, JoFrances	Smith, Randall	



April 7th

WSU SOM ENDOWMENT

The Wayne State University School of Medicine provides an opportunity for alumni to create endowments in support of their institution and also support the WSSS. For example, if Dr. John Smith wished to create the “Dr. John Smith Endowment Fund”, he could donate \$25,000 to the WSU SOM and those funds would be left untouched but, by their present, help with attracting other donations. The interest at the rate of 4% per year (\$1000) could be directed to the WSSS on an annual basis to help the WSSS continue its commitment to improving the education of surgical residents. Anyone who desires to have this type of named endowment established with the interest of that endowment supporting the WSSS should contact Ms. Lori Robitaille at the WSU SOM> She can be reached by email at lrobitai@med.wayne.edu.