

O.R. TEAM PROVIDES SEND-OFF LUNCHEON FOR DR. CHOICHI SUGAWA



Inside this issue:

<i>O.R. Team Provides Send Off Luncheon for Dr. Sugawa</i>	1-8
<i>Tube Troubles</i>	9-11
<i>Productivity</i>	11
<i>Down Memory Lane</i>	12-13
<i>WSU Conferences</i>	14
<i>WSSS President's Letter</i>	15
<i>WSSS Dues</i>	16
<i>WSSS Members</i>	17-18




2021 WSSS OFFICERS

- President:**
Scott Davidson (WSU/GS 1990/96)
- Vice-President:**
Larry Narkiewicz (WSU/GS 2004/09)
- Secretary-Treasurer:**
Pamela Johnson (WSU/GS 1984/89)
- Members-at-Large:**
Bruce McIntosh (WSU/GS 1989/94)
Jay Dujon (WSUGS 2011)
Robert Holmes (WSUGS 1983)
- Resident Member:**
Peter Cmorej (WSUGS 2021)

Dr. Choichi Sugawa was highly respected not only for his technical skills, but also for being a gentleman. The operating room team decided that he should have a farewell luncheon as a token of their recognition of his skills and his gentlemanly demeanor. This effort was led by Ms. Jeanne Russell and was supported by many of the other O.R. personnel; essentially everyone contributed, and there is not enough space in this brief report to give credit to everyone by name.

All aspects of the luncheon were carefully prepared. The food was all Japanese and provided by Dr. Sugawa's favorite restaurant, "Noble Fish," which provided all sorts of Japanese goodies, as well as Dr. Sugawa's favorite, sushi. Pictures of the different food provided by Noble Fish are included in the report.

During this retirement luncheon, many of the O.R. personnel, Radiology personnel, surgeons, and relatives of Dr. Sugawa were able to celebrate the retirement of Dr. Sugawa.



Dr. Choichi Sugawa sitting in his O.R. Office



Dr. Choichi and Mrs. Natsuko Sugawa



(Left to right) Dr. Anna Ledgerwood (WSUGS 1972), Dr. Karen Carbone, CMO of DRH, Dr. Michael White (WSU/GS 1990/97), celebrate the Japanese luncheon with Mrs. Natsuko Sugawa, and Dr. Choichi Sugawa

AUGUST 2021

O.R. TEAM PROVIDES SEND-OFF LUNCHEON FOR DR. CHOICHI SUGAWA, cont..



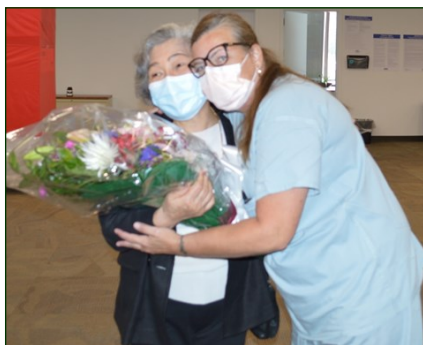The special cake and decorations to celebrate Dr. Sugawa's retirement



Many of the O.R. staff and surgeons who have worked with Dr. Sugawa over the past half century



Dr. Sugawa's "Happy Retirement" cake



Ms. Russell presents Mrs. Sugawa with a retirement bouquet



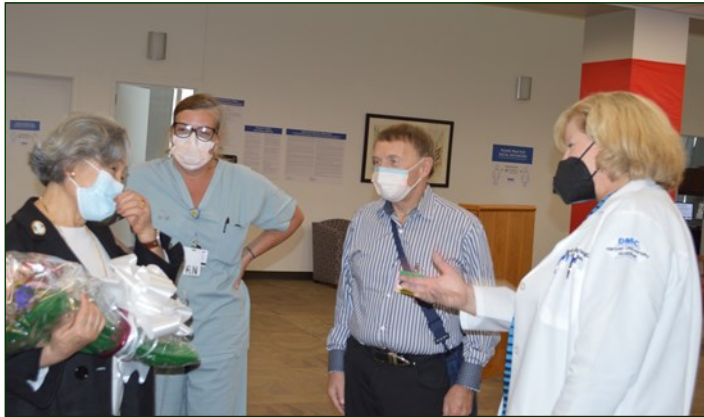Dr. Sugawa celebrates with Mr. Valdor Haglund, CRNA (left) and Dr. Samuel Perov (right)



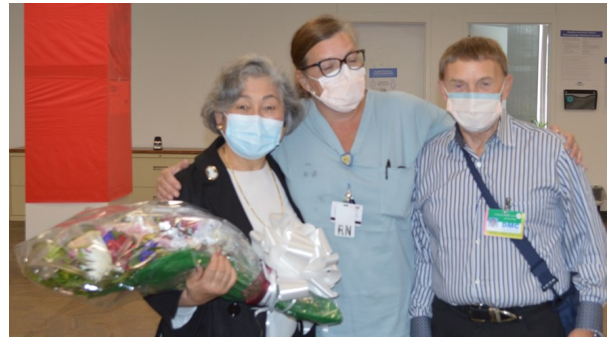Continue page 3

AUGUST 2021

O.R. TEAM PROVIDES SEND-OFF LUNCHEON FOR DR. CHOICHI SUGAWA, cont..



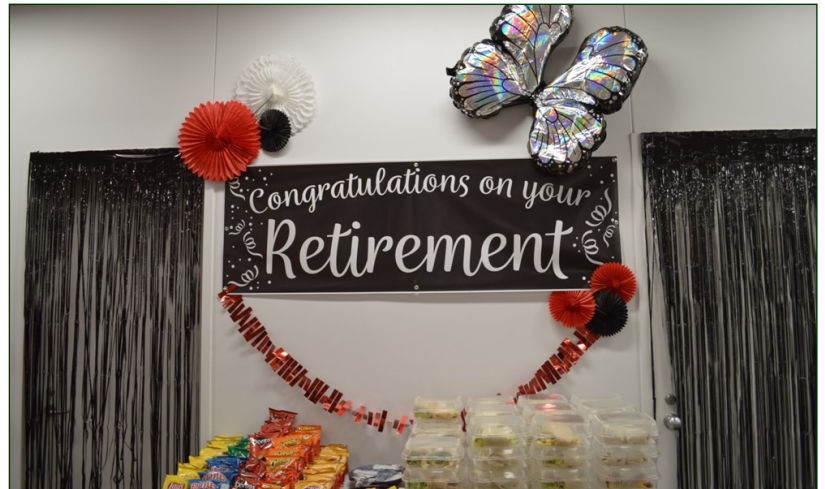Mrs. Sugawa, holding her bouquet, with Ms. Russell, Dr. Samuel Perov, current Chief of Anesthesiology, and Dr. Karen Carbone, current CMO of DRH



Mrs. Sugawa, holding bouquet, Ms. Russell, and Dr. Samuel Perov



Dr. Choichi Sugawa and Dr. Charlie Lucas (WSU/GS 1962/67) celebrate their more than 50 years together



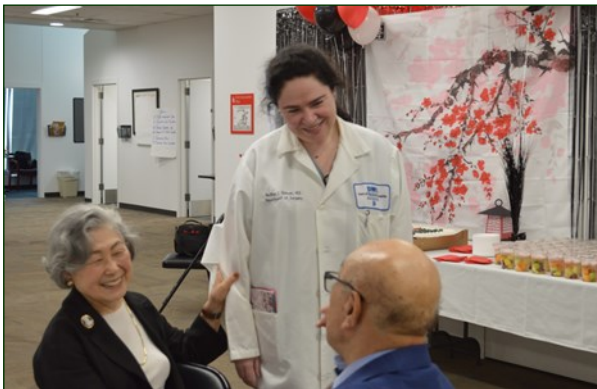Continue page 4

AUGUST 2021

O.R. TEAM PROVIDES SEND-OFF LUNCHEON FOR DR. CHOICHI SUGAWA, cont..



Dr. Sugawa is trying to educate Dr. Lucas on how to eat sushi, as Ms. Camille Neal looks on with amused eyes



Dr. Heather Dolman (WSU/GS 2000/06) celebrates the retirement with Dr. and Mrs. Sugawa



(Left to right) Dr. S.R.A. Paruchuri, Dr. Choichi Sugawa, and Dr. Todd Lavery (WSUGS 2012) celebrate at the luncheon



Mr. Fred Davis, who worked closely with Dr. Sugawa during his endoscopic examinations, celebrates with Dr. Sugawa



Dr. Sugawa measures the circumference of Dr. Roobah Mansour's (WSUGS 2015) bicep



Continue page 5

AUGUST 2021

O.R. TEAM PROVIDES SEND-OFF LUNCHEON FOR DR. CHOICHI SUGAWA, cont..



Drs. Roozbeh Mansour (WSUGS 2015, Dr. Heather Dolman (WSU/GS 2000/2006), and Dr. Al Baylor (WSUGS 2005) discuss the fine Japanese food, as Dr. Sugawa looks on



Ms. Nancy Evans, Ms. Jennifer Metzner, Ms. Camille Neal, and Ms. Jeanne Russell celebrate the luncheon with Dr. Sugawa




Dr. Marc Moisi, neurosurgeon, Dr. Tony Joseph who is practicing in the north-west suburb, and Dr. Todd Lavery (WSUGS 2012) celebrate with Dr. Sugawa



Dr. Choichi Sugawa celebrates his retirement with Dr. Charlie Lucas (WSU/GS 1962/67) and Dr. Anna Ledgerwood (WSUGS 1972)



Dr. Jim Tyburski (WSUGS 1992) congratulates Dr. Sugawa on his retirement



Dr. Jessica Dornbush (WSUGS 2017) stops by to congratulate Dr. Sugawa on his retirement

Continue page 6

AUGUST 2021

O.R. TEAM PROVIDES SEND-OFF LUNCHEON FOR DR. CHOICHI SUGAWA, cont..



Dr. Sugawa having fun with Charlie Lucas, Heather Dolman, Anna Ledgerwood, and his bride, Mrs. Natsuku Sugawa



Dr. Harold Munchnik , Internal Medicine endoscopist celebrates with Dr. and Mrs. Sugawa



Mr. Eugene Tennison and Mr. Roderick Besant, in the Department of Radiology, celebrate with Dr. Sugawa



Dr. Larry Diebel (WSU/GS 1980/86) and Dr. David Edelman (WSU/GS 2002/09) celebrate with Dr. Sugawa



O.R. staff, Ms. Carla Cole and Ms. Lynn Hollins celebrate Dr. Sugawa's retirement



Continue page 7

AUGUST 2021

O.R. TEAM PROVIDES SEND-OFF LUNCHEON FOR DR. CHOICHI SUGAWA, cont..



Dr. Al Baylor (WSUGS 2005) congratulates Dr. Sugawa on his retirement



Ms. Helen Prombley shares her work experiences with Dr. Sugawa with his bride, Mrs. Natsuku Sugawa



Dr. Samantha Tarras (WSUGS 2011) stops by to congratulate Dr. Sugawa on his retirement



Mr. Ed McClure congratulates Dr. Sugawa on his retirement



O.R. staff, Ms. Jeanne Russell, Ms. Jessica Marcus, and Ms. Ryan Haddix celebrate Dr. Sugawa's retirement



Dr. Harold Munchnik, Internal Medicine endoscopise, and Dr. Rahul Vaidya celebrate the retirement luncheon with Dr. and Mrs. Sugawa



Continue page 8



AUGUST 2021

O.R. TEAM PROVIDES SEND-OFF LUNCHEON FOR DR. CHOICHI SUGAWA, cont..

There were so many who came to congratulate and celebrate Dr. Choichi Sugawa and his bride, Mrs. Natsuku Sugawa's, retirement



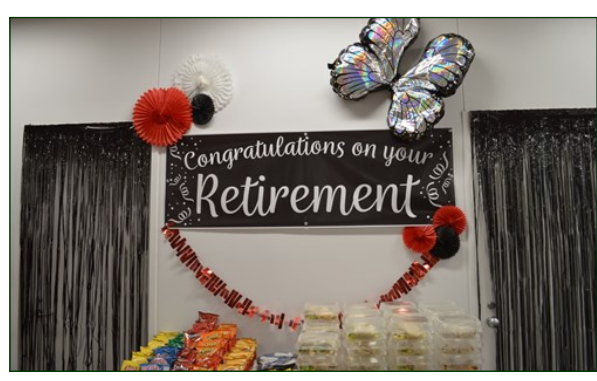
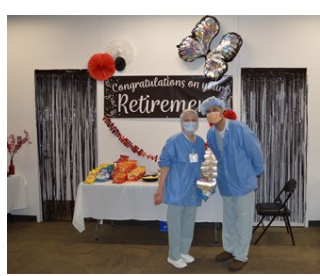Ms. Karen Bene and Ms. Lisa Aquilina celebrate Dr. Sugawa



Ms. Nancy Burbach and Mr. Mark Brady congratulate Dr. Sugawa on his retirement



Ms. Jessica Marcus, Ms. Karen Pouvell, and



AUGUST 2021

TUBE TROUBLES

The busy surgeon is constantly dealing with different types of tubes in order to facilitate a successful outcome. Like all things in life, however, there are no free lunches. The following represents some examples of where tubes can lead to difficulties and problems.

Many moons ago, a middle-aged patient was admitted and treated for acute cholecystitis by means of intravenous fluid resuscitation, antibiotics, and nasogastric suction. She was a tiny bit tachypneic so that nasotracheal oxygen was ordered. Within minutes following the initiation of nasal oxygen, the patient developed severe abdominal pain and abdominal distension. Immediate examination identified that the patient had peritonitis, and she was rushed to the operating room, on the assumption that she had ruptured her gallbladder. At surgery, she was found to have a tear in the anterior wall of the stomach, which was markedly distended. The repair was closed primarily, and the patient did well. Post-operatively, the nursing staff were trained how to recognize a nasogastric tube and to not infuse 5L per minute of oxygen thru the nasogastric tube.

A middle-aged woman presented with Charcot's triad with fever, right upper quadrant pain, and jaundice. Imaging studies suggested that she had a common bile duct stone that could not be removed by ERCP. She underwent open cholecystectomy with common duct exploration and removal of common duct stones, followed by placement of a T-tube. A Jackson-Pratt drain was left under the liver because there had been a significant degree of inflammation in the hepatic bed. She recovered nicely from operation, and the student was directed to remove the Jackson-Pratt drain when it no longer was yielding any drainage. Yes, your suspicions are correct; the student removed the T-tube! Fortunately, the remaining Jackson-Pratt drain was able to drain the small amount of bile that emanated over the next three or four days from the hole in the common bile duct.

A young man presented to the Emergency Department with a stab wound to the chest, which caused a pneumothorax. The patient was stable and was treated with a chest tube. This resulted in a large amount of bubbling from the chest tube and failed to cause expansion of the lung. The resident presented the problem to the attending surgeon, and he recommended that the patient have right thoracotomy for repair of a large bronchus injury. When the attending saw the patient in the Emergency Department, the attending pointed out the difference in contour between a chest tube, which is round, and a sump tube, which has multiple different sides to it. That resident never again confused a chest tube with a sump tube.



Continue page 10

AUGUST 2021

TUBE TROUBLES, cont..

A middle-aged driver of a semi tractor-trailer involved in a multi-vehicle crash on the freeway was admitted confused, incoherent, and hypoxic. He had tachycardia and was in obvious respiratory distress with a flail of the left anterior chest and sternum. He also had a skull fracture and a fracture of the left humerus. He underwent tracheostomy and a feeding jejunostomy. On post injury day two, he developed a tachyarrhythmia with hypoxia and hypotension. This responded to cardioversion, and the arrhythmia responded to Procainamide. He eventually stabilized, was treated for pneumonia, and remained agitated and confused. He pulled out his J-tube on the 17th day, and it was replaced with a Foley catheter. He was continued on tube feedings. His tracheostomy tube was capped, and he was transferred from the ICU to the acute care ward. Three days later, he developed abdominal distension, abdominal pain, and vomited. He was noted to be in atrial fibrillation with a rate of 156, and his procainamide levels were very low. An abdominal x-ray showed dilated stomach and proximal jejunum with what appeared to be the distended balloon of the Foley catheter. The Foley balloon was aspirated and returned 80 mL of Procainamide. His distension resolved, and he was re-started on tube feedings. He was eventually extubated and discharged home. It is important that all members of the team know the purpose of a tube and all of its components.

Many of our critically ill patients have problems with dietary intake and are candidates for placement of some type of feeding tube. Placement of a PEG tube is good when patients do not have problems with traumatic brain injury or stroke, which interferes with lower esophageal sphincter function. Such patients are candidates for jejunostomy feeding tubes. When a patient has placement of a feeding jejunostomy and has unusual diarrhea following the break up of an adynamic ileus, one should question the placement of the feeding jejunostomy. Such tubes have been placed in the transverse colon and in the distal ileum. The ligament of Treitz must be identified during the operation for placement of a feeding jejunostomy.

Not infrequently, patients who are candidates for nasogastric tube decompression develop problems with coughing following tube placement. Sometimes this leads to imaging studies demonstrating that the nasogastric tube is in the right main stem bronchus. Whenever fitful coughing occurs after the placement of an Ng tube, it is better to remove the tube so that nobody knows who actually placed the Ng tube in the right main stem bronchus.



Continue page 11

AUGUST 2021

TUBE TROUBLES, cont..

Many years ago, ultrasound was not the routine examination for a patient with blunt abdominal trauma; the popular procedure was diagnostic peritoneal lavage. Indeed, many of the white-haired surgical alumni were able to complete the diagnostic peritoneal lavage within five minutes of patient arrival in the Emergency Department. One of our retired surgeons did a peritoneal lavage on a patient who had blunt injury and was distressed to see that there was a marked increase in the nasogastric output, which had the same consistency as the lavage fluid. The patient was taken directly to the operating room and found to have a hole in the anterior wall of the antrum, which explained why the lavage fluid immediately came out the nasogastric tube. One of the lessons learned is that you never do a peritoneal lavage on a patient who does not have a functioning nasogastric tube and, therefore, has a collapsed stomach. Most of our residents have never performed a diagnostic peritoneal lavage because of the 21st century advances in ultrasound.

A Foley catheter is a critical device for following the critically ill patient with either injury or sepsis. Sometimes when the urine output is essentially non-existent, a patient will get large volumes of fluid in order to restore vascular volume. When the patient with a stable blood pressure continues to have low urine output and develop lower abdominal pain and distension, the problem may not be intra-abdominal hemorrhage but rather a plugged Foley catheter. One such patient who would be considered for laparotomy had the rapid removal of two liters of urine following the replacement of a plugged Foley catheter.

The above are some interesting, somewhat humorous complications related to tubes. Please send your anecdotes to the rest of the members of the WSSS clan.




PRODUCTIVITY



THE REWARD OF SCHOLARSHIP

Dr. Awni Shahait (WSU/GS 2021) was always in the 99 percentile of his in-training examinations throughout his residency. His excellent retention of facts allowed him to be an excellent teacher for the other residents on the team. He has been rewarded for this outstanding diligence to academics by obtaining an Endocrine Surgery Fellowship at Augusta University. The editor predicts that he will chair a Section of Endocrinology later on in his academic career!



Dr. Awni Shahait



"EXCERPTS FROM LOG BOOK" - DOWN MEMORY LANE

Anna M. Ledgerwood, MD

August 1970

Emergency Surgery night team: Z. Asuncion, J. Primrose, K. Kish (intern), rotators, Sinai third-year, St. John's third-year, Providence second-year, Sinai first-year



Dr. Anna Ledgerwood

8/7/70: Attending staff, Dr. A. Walt

AP: Acute appendicitis. Rx appendectomy.

RW: Gunshot wound left liver, right hemothorax. Suture liver, cholecystostomy, right chest tube.

NJ: GSW right scapula, right clavicle with penetration into right anterior neck. Had ligation arterial bleeders at the fracture site. Exploration right supraclavicular area with ligation bleeders.

AP: Stab penetrating upper abdomen. Exploration non-therapeutic.

AL: Stab abdomen. Question of free air on x-ray. Exploratory lap showed non-penetrating wound.

DD: Perirectal abscess. Treated with I&D.

8/8/70: Staff, Dr. C. Lucas

JW: Laceration extensor tendon--repaired.

RW: Stab right neck. Suture lacerated bleeders.

WC: GSW stomach, right kidney, IVC, and duodenum. Repair laceration stomach, duodenum, and IVC. Right nephrectomy, Jaboulay pyloroplasty.

SW: GSW right kidney and liver. Treated with wedge resection right kidney, cholecystostomy tube.

8/9/70: Staff, Dr. Silva

VP: GSW liver. Sutured with cholecystostomy

Continue page 13



DOWN MEMORY LANE

Anna M. Ledgerwood, MD

JB: GSW left diaphragm, spleen, liver, stomach, splenic flexure colon, and left renal pedicle. Treated with repair of diaphragm, splenectomy, and nephrectomy with colostomy.

TM: GSW right liver. Sutured and Penrose drain.

8/10/70: Staff, Dr. Ellis

JD: Stab gallbladder with bile spillage. Treated with cholecystectomy and drains.

ET: Stab abdomen. Exploratory lap. Wound did not penetrate. Patient treated for gonorrhoea.

WK: Small bowel obstruction secondary to mass in terminal ileum. Treated with right colectomy and gastrostomy with small bowel decompression.

JC: Acute appendicitis. Treated with appendectomy.

8/11/70: Staff, Dr. G. Shannon

CA: GSW left liver, stomach, colon, spleen, superior mesenteric artery branch. Suture liver, repair stomach, splenectomy, Penrose drain, and colostomy.

PW: GSW stomach, pancreas, and liver. Not bleeding. Sutured stomach, t-tube common duct.

8/12/70: Staff, Dr. R. Wilson

MC: GSW left lobe of the liver. Addict. Treated with debridement, suture, and cholecystostomy.

8/13/70: Staff, Dr. G. Shannon

JJ: Status post splenectomy. I&D subphrenic abscess with twelfth rib resection.

ST: Stab left face. Exploration wound with control bleeding.

LS: GSW right anterior chest, laceration right brachial artery. Repair laceration of brachial artery.

JC: GSW left femoral artery with aneurysmal formation. Resection with end-to-end repair



WSU MONTLY CONFERENCES

2021

Death & Complications Conference
Every Wednesday from 7-8



Didactic Lectures — 8 am
Kresge Auditorium

***The weblink for the New WebEx Room:
<https://davidedelman.my.webex.com/meet/dedelman>***

Wednesday, August 4

Death & Complications Conference

**“Genetics and Genomics in the Study of High-Risk /
Triple Negative Breast Cancer Associated with African Ancestry”**

Lisa A. Newman, MD, MPH, FACS, FASCO, FSSO

Chief, Division of Breast Surgery

Medical Director & Founder, International Center for the Study of Breast Cancer Subtypes
Weill Cornell Medicine/New York Presbyterian Hospital Network

Wednesday, August 11

Death & Complications Conference

“Global Surgery”

Todd Lavery, MD

Wayne State University Michael & Marian Ilitch Department of Surgery

Wednesday, August 18

Death & Complications Conference

“To Be Determined”

Lawrence Diebel, MD

Wayne State University Michael & Marian Ilitch Department of Surgery

Wednesday, August 25

Death & Complications Conference

“To Be Determined”

Jennifer Bradley, MD

Muskegon Surgical Associates, PLC
Muskegon, Michigan



Department of Surgery
6C/UHC, 4201 St. Antoine
Detroit, Michigan 48201
(313) 577-5013
FAX: 577-5310



March 8, 2021

Dear WSSS Alumni and Friends:

The Wayne State Surgical Society (WSSS) continues to thrive, offering support to our members and the current general surgical residents at WSU. As the president of the WSSS, I would like to review our new business year-end report on the Society's activities in 2020. Our annual meeting of the American College of Surgeons was supposed to take place in Chicago, but as everyone knows, the meeting was held virtually and, of course, we did not have our annual reception and report to the membership by our chairman, Dr. Don Weaver. This year's meeting of the ACLS will be in Washington, D.C. from October 24-28, and we will enjoy a good reunion of the department on Tuesday evening. The details of where the meeting will take place for the alumni will be forthcoming in a subsequent monthly report. The WSSS supports the senior surgical residents with their attendance at that meeting, and each of the graduating residents will give the alumni a summary as to what their plans are for the next step in their career after completing their surgical residency.

The Society also sponsors the annual WSSS Lectureship in memory of Dr. Walt. The 2020 Lecturer was presented virtually by Dr. Joseph Maroon, who is a Clinical Professor of Neurosurgery at the University of Pittsburgh. Dr. Maroon presented an outstanding talk, "From Icarus to Aequanimitas -Overcoming Adversity and Building Resilience." Dr. Maroon summarized the statements made by Sir William Osler when he addressed the University of Pennsylvania medical students in 1890. Dr. Osler always emphasized the importance of a good relationship between physician and patient. Dr. Maroon's presentation highlighted how Icarus was directed to avoid hubris when he flew with waxed wings and was told by his father to not fly close to the sun, lest the heat melt the wax on the wings, and not to fly close to the water, lest the waves moisten his wings and cause them to sink into the ocean. He emphasized how he (Dr. Maroon) was a workaholic when he became a member of the Department of Surgery at the University of Pittsburgh. He focused on his successful research, clinical care, publications, and left little time for anything else, including family. While at the peak of his academic career, his dad died and his wife took the kids and said goodbye. Faced with this overwhelming challenge, he dropped out of surgery and worked at a truck stop, which his father had owned, and he experienced financial difficulty in the midst of his depression. He read the book by William Dansforth, "Balance Your Life," which emphasized the importance of a spiritual life, physical activity, and communication with others. Dr. Maroon became a competitive runner, won many triathlons, avoided anti-depressant medications, ate a balanced diet without fatty foods, and returned to his first love, namely, surgery. While doing a triathlon in Hawaii, Dr. Maroon noted that the triple amputee who lost both legs and one arm fighting for our country was just ahead of him, running on metal legs. The individual was about to give up when Dr. Maroon badgered him and told him that he must finish the race, which he did. They became close friends, and later the two of them climbed Mount Kilimanjaro in Japan. His presentation was outstanding, and those who had the privilege of listening to this virtual presentation were rewarded.

This year's WSSS Lectureship will be provided by Dr. David Spain, one of our own medical school graduates who credits his favorite teacher, Dr. Anna Ledgerwood, for directing him to a career in Trauma/Acute Care Surgery. Dr. Spain is the Trauma Director, Critical Care Director, and Vice-Chairman of the Department of Surgery at Stanford University. He is the past president of the American Association for the Surgery of Trauma. He will give an outstanding WSSS Lectureship, which will be provided on Wednesday, November 10 at the Harper Hospital Kresge Auditorium. This will certainly be an outstanding lecture, and the membership should plan to come downtown to support Dr. Spain in his effort. Those who cannot make it downtown should follow the directions provided by Dr. David Edelman, our program director, in order to hear the lecture virtually.

The Detroit Trauma Symposium for 2020 was quite successful, even though the entire symposium was done virtually. The presenters were all outstanding, and their presentations came thru quite clearly via ZOOM. Dr. Diebel was able to provide appropriate questions for each of the presenters, who provided excellent responses to these questions. The virtual technique allowed these lectures to be seen online for approximately five weeks after the symposium ended. This year's Trauma Symposium has already been planned and will occur on November 11-12 at the MGM Casino in downtown Detroit. Dr. Diebel already has a fine list of outstanding presenters who are going to come to Detroit and make personal presentations, rather than having the meeting done virtually. You should set those days aside and plan to come down to hear these great presentations and mix with your fellow members of the WSSS.

Your WSSS membership also covers your admission to the annual Detroit Trauma Symposium. Incidentally, the Detroit Trauma Symposium is the oldest trauma symposium in the country and has been very successful under the leadership of Dr. Diebel. He typically attracts over 700 people to this excellent event. The details as to the specific speakers will come out in one of the later editions of the monthly report.

The WSSS membership is currently approaching 150 members, with over 70 of those members being Charter Life members who have, or are in the process of, donating \$10,000 to the Society, tax-deductible! **If you are not receiving the newsletter, please let us know your e-mail address so that you can be included to receive this very fun and informative newsletter for all the alumni of the Department of Surgery.** It gives me great pleasure to tell you that we have over \$219,432 in the bank, and are in the process of investing a portion to ensure the Society will exist in perpetuity. Consider becoming a Life Member, invest in the future, and one of these outstanding residents may just become your partner!

Typically, enclosed with this letter is a ballot for new officers and Board members. However, the ballot will not be included this year, since none of the officers and Board members had an opportunity to carry out their functions for 2020 and have agreed to continue in the same function for 2021. Also included with this mailing is the form for your Annual Dues. I always thought the standards and skills learned during my residency formed the foundation for my professional career. The Society offers the opportunity to continue a relationship with the program, both by continued fellowship with peers and mentors, as well as the support of those who will be replacing us when we retire. I think the WSSS is worthy of your support. Serving as our Society president this year will be an honor. The WSU Michael and Marian Ilitch Department of Surgery and the WSSS is responsible for a large part of our success as surgeons. It is an organization that brings old friends together with mentors and future partners. It is worthy of our participation and support.

Sincerely yours,
Scott Davidson, MD, FACS
President, Wayne State Surgical Society



**Wayne State Surgical Society
2021 Donation**

Name: _____

Address: _____

City/State/Zip: _____

Service Description	Amount
---------------------	--------

2021 Dues Payment _____	\$200	_____
-------------------------	-------	-------

My contribution for "An Operation A Year for WSU" _____		_____
---	--	-------

*Charter Life Member _____	\$1000	_____
----------------------------	--------	-------

Total Paid _____

Payment by Credit Card

Include your credit card information below and mail it or fax it to 313-993-7729.

Credit Card Number: _____

Type: MasterCard Visa Expiration Date: (MM/YY) _____ Code _____

Name as it appears on card: _____

Signature: _____

Billing address of card (if different from above):

Street Address _____

City _____ State _____ Zip Code _____

*I want to commit to becoming a charter life member with payment of \$1000 per year for the next ten (10) years.

Send check made payable to **Wayne State Surgical Society** to:

Charles Lucas, MD
Department of Surgery
Detroit Receiving Hospital, Room 2V
4201 St. Antoine Street
Detroit, Michigan 48201

MARK YOUR CALENDARS

*80th American Association of the Surgery of Trauma and Clinical Congress of Acute Care Surgery Annual Meeting
September 29-October 02, 2021
Kilton Atlanta
Atlanta, Georgia*

*American College of Surgeons Clinical Congress
October 23-27, 2021
Virtual Event*

*Detroit Trauma Symposium Annual Meeting
November 4-5, 2021
Detroit, Michigan*

*Western Surgical Association Annual Meeting
November 6-9, 2021
Renaissance Indian Wells Resort & Spa
Indian Wells, California*



Please Update Your Information

The WSUSOM Department of Surgery wants to stay in touch. Please email Charles Lucas at clucas@med.wayne.edu to update your contact information.



Missing Emails

Over the years the WSU Department of Surgery has lost touch with many of its alumni. If you know the email, address, or phone number of the following WSU Department of Surgery Residency Program graduates please email us at clucas@med.wayne.edu with their information so that we can get them on the distribution list for the WSU Department of Surgery Alumni Monthly Email Report.

Mohammad Ali (1973)

David B. Allen (1992)

Tayful R. Ayalp (1979)

Juan C. Aletta (1982)

Kuan-Cheng Chen (1976)

Elizabeth Colaiuta (2001)

Fernando I. Colon (1991)

David Davis (1984)

Teoman Demir (1996)

Judy A. Emanuele (1997)

Lawrence J. Goldstein (1993)

David M. Gordon (1993)

Raghuram Gorti (2002)

Karin Haji (1973)

Morteza Hariri (1970)

Harrison, Vincent L. (2009)

Abdul A. Hassan (1971)

Rose L. Jumah (2006)

R. Kambhampati (2003)

Aftab Khan (1973)

Samuel D. Lyons (1988)

Dean R. Marson (1997)

Syed A. Mehmood (2007)

Toby Meltzer (1987)

Roberto Mendez (1997)

Mark D. Morasch (1998)

Daniel J. Olson (1993)

David Packer (1998)

Y. Park (1972)

Bhavik G. Patel (2004)

Ami Raafat (1998)

Kevin Radecki (2001)

Sudarshan R. Reddy (1984)

Renato G. Ruggiero (1994)

Parvid Sadjadi (1971)

Samson P. Samuel (1996)

Knavery D. Scaff (2003)

Steven C. Schueller (1974)

Anand G. Shah (2005)

Anil Shetty (2008)

Chanderdeep Singh (2002)

D. Sukumaran (1972)

David G. Tse (1997)

Christopher N. Vashi (2007)

Larry A. Wolk (1984)

Peter Y. Wong (2002)

Shane Yamane (2005)

Chungie Yang (2005)

Hossein A. Yazdy (1970)

Lawrence S. Zachary (1985)



International
Beer Day

Friday, August 6th

Wayne State Surgical Society

The Wayne State Surgical Society (WSSS) was established during the tenure of Dr. Alexander Walt as the Chairman of the Department of Surgery. WSSS was designed to create closer contact between the current faculty and residents with the former resident members in order to create a living family of all of the WSU Department of Surgery. The WSSS also supports department activities. Charter/Life Membership in the WSSS is attained by a donation of \$1,000 per year for ten years or \$10,000 prior to ten years. Annual membership is attained by a donation of \$200 per year. WSSS supports a visiting lecturer each fall and co-sponsors the annual reception of the department at the annual meeting of the American College of Surgeons. Dr. Jeffrey Johnson (WSU/GS 1984) passed the baton of presidency to Dr. Scott Davidson (WSU/GS 1990/96) at the WSSS Gathering during the American College of Surgeons meeting in October 2018. Members of the WSSS are listed on the next page. Dr. Davidson continues in the hope that all former residents will become lifetime members of the WSSS and participate in the annual sponsored lectureship and the annual reunion at the American College of Surgeons meeting.



*Members of the Wayne State Surgical Society
Charter Life Members*

Ahn, Dean	Bouwman, David	Fromm, David G	Johnson, Pamela D.	Missavage, Anne	Sarin, Susan	Walt, Alexander (Deceased)
Albaran, Renato G	Bradley, Jennifer	Galpin, Peter A.	Kovalik, Simon G.	Montenegro, Carlos E.	Shapiro, Brian	Weaver, Donald
Allaben, Robert D. (Deceased)	Cirocco, William C.	Gayer, Christopher P.	Lange, William (Deceased)	Narkiewicz, Lawrence	Silbergleit, Allen	Whittle, Thomas J.
Ames, Elliot L.	Clink, Douglas	Gerrick Stanley	Lau, David	Nicholas, Jeffrey M.	Smith, Daniel	Williams, Mallory
Amirikia, Kathryn C.	Colon, Fernando I.	Grifka Thomas J. (Deceased)	Ledgerwood, Anna M.	Novakovic, Rachel L.	Smith, Randall W.	Wilson, Robert F.
Anslow, Richard D.	Conway, W. Charles	Gutowski, Tomasz D.	Lim, John J.	Perrone, Erin	Stassinopoulos, Jerry	Wood, Michael H.
Sntoniolli, Anita L.	Davidson, Scott B.	Herman, Mark A.	Lucas, Charles E.	Porter, Donald	Sullivan, Daniel M.	
Auer, George	Dujon, Jay	Hinshaw, Keith A.	Malian, Michael S.	Ramnauth, Subhash	Sugawa, Choichi	
Babel, James B.	Edelman, David A.	Holmes, Robert J.	Maxwell, Nicholas	Rector, Frederick	Tuma, Martin	
Bassett, Joseph	Francis, Wesley	Huebl, Herbert C.	McGuire, Timothy	Rose, Alexander	vonBerg, Vollrad J. (Deceased)	
Baylor, Alfred	Flynn, Lisa M.	Johnson, Jeffrey R.	McIntosh, Bruce	Rosenberg, Jerry C.	Washington, Bruce C.	



Members of the Wayne State Surgical Society—2021 Dues

Alpendre, Cristiano V.	Dulchavsky, Scott A.	Kaderabek, Douglas J.	Mueller, Michael J.	Thoms, Norman W.
Asfaw, Ingida	Edwards, Ryan	Klein, Michael D.	Noorily, Michael	Vasquez, Julio
Bambach, Gregory A.	Fernandez-Gerena, Jose	Kosir, Mary Ann	Paley, Daniel S.	Ziegler, Daniel W.
Baylor, Alfred	Gallick, Harold	Larson, Sarah	Phillips, Linda G.	Zoellner, Steven M.
Bucci, Lorenzo	Goltz, Christopher J.	Liebold, Walt	Schwarz, Karl W.	
Carlin, Arthur	Hamamdjian, Khatch	Lopez, Peter	Shaheen, Kenneth W.	
Dawson, Konrad L.	Hilu, John	Malian, Michael S.	Siegel, Thomas S.	
Dente, Christopher	Jeffries, Christopher	McGee, Jessica D.	Taylor, Michael G.	
Dolman, Heather	Joseph, Anthony	Meade, Peter C.	Thomas, Gregory A.	



Monday, August 16th

*Operation-A-Year
January 1—December 31, 2021*



The WSU department of Surgery has instituted a new group of alumni who are remembering their training by donating the proceeds of one operation a year to the department. Those who join this new effort will be recognized herein as annual contributors. We hope that all of you will remember the department by donating one operation, regardless of difficulty or reimbursement, to the department to help train your replacements. Please send you donation to the Wayne State Surgical Society in care of Dr. Charles E. Lucas at Detroit Receiving Hospital, 4201 St. Antoine Street (Room 2V), Detroit, MI, 48201.

Albaran, Renato G.	Cirocco, William C.	Gallick, Harold	Holmes, Robert J.	Lim, John J.	Missavage, Anne	Siegel, Thomas S.	Whittle, Thomas J.
Anslow, Richard D.	Conway, W. Charles	Gayer, Christopher P.	Huebel, Hubert C.	Lopez, Peter	Nicholas, Jeffrey	Silbergleit, Allen	Williams, Mallory
Antoniolli, Anita L.	Davidson, Scott	Gutowski, Tomasz D.	Johnson, Jeffrey R.	Malian, Michael	Novakovic, Rachel L.	Smith, Randall W.	Wood, Michael H.
Anthony, Joseph	Dujon, Jay	Hamamdjian, Khatch	Johnson, Pamela D.	Maxwell, Nicholas	Perrone, Erin	Sugawa, Choichi	
Bambach, Gregory A.	Edelman, David A.	Herman, Mark A.	Joseph, Anthony	McGuire, Timothy	Porter, Donald	Sullivan, Daniel M.	
Bradley, Jennifer	Francis, Wesley	Hinshaw, Keith A.	Ledgerwood Anna M.	McIntosh, Bruce	Sankaran, Surya	Tuma, Martin	

WSU SOM ENDOWMENT

The Wayne State University School of Medicine provides an opportunity for alumni to create endowments in support of their institution and also support the WSSS. For example, if Dr. John Smith wished to create the “Dr. John Smith Endowment Fund”, he could donate \$25,000 to the WSU SOM and those funds would be left untouched but, by their present, help with attracting other donations. The interest at the rate of 4% per year (\$1000) could be directed to the WSSS on an annual basis to help the WSSS continue its commitment to improving the education of surgical residents. Anyone who desires to have this type of named endowment established with the interest of that endowment supporting the WSSS should contact Ms. Lori Robitaille at the WSU SOM> She can be reached by email at lrobitai@med.wayne.edu.