

MARCH 2022

Dr. Gary W. Chmielewski, MD



March 13th

Inside this issue:

<i>Dr. Gary W. Chmielewski</i>	1-4
<i>Dr. Linda Philips</i>	5-6
<i>Dr. Melvyn Westreich: Memories of a Special M&M Conference</i>	7-14
<i>Productivity</i>	15
<i>Warrior Medicine: Department of Surgery News</i>	16
<i>Down Memory Lane</i>	17-18
<i>WSU Conferences</i>	19
<i>WSSS Dues</i>	20
<i>WSSS Members</i>	21-22

2022 WSSS OFFICERS

President:

Scott Davidson (WSU/GS 1990/96)

Vice-President:

Larry Narkiewicz (WSU/GS 2004/09)

Secretary-Treasurer:

Pamela Johnson (WSU/GS 1984/89)

Members-at-Large:

Bruce McIntosh (WSU/GS 1989/94)

Jay Dujon (WSUGS 2011)

Robert Holmes (WSUGS 1983)

Resident Member:

Dr. Michael Carge (WSUGS 2022)

Dr. Ashley Malach (WSUGS 2022)

Dr. Gary Chmielewski (WSUGS/TS 1993/96) was born and raised in Chicago. He attended college at the University of Dayton and then medical school at Loyola. After finishing medical school in 1988, Gary came to Detroit, where he finished his General Surgery residency in 1993 and his cardiothoracic fellowship training in 1996. He was proud to have been chosen as the chief resident in both programs.



Dr. Gary Chmielewski

Following his cardiothoracic training, Gary joined Dr. Robert Welsh (WSUGS 1993) in the practice of Cardiothoracic Surgery at the William Beaumont Hospital. The two of them became very busy and took on two additional partners, so that they quickly became one of the busiest cardiothoracic groups in Michigan.

During these early years, Dr. Chmielewski performed the first pulmonary resection by the video-assisted thorascopic (VAT) technique in the Detroit area, which quickly attracted more patients to their practice group. Gary presented their cumulative experiences with the VAT resections at the Southern Surgical Association meeting in 2008. This is one of the most prestigious surgical associations in the country.

Other innovations that Gary and his teammates made in the early part of the 21st century included utilizing minimally invasive techniques for esophageal surgery and mediastinal surgery. This continued expansion by Gary and his teammate allowed them to be the authors of many peer reviewed publications, and they made many regional and state presentations regarding their surgical experiences. They also introduced radiofrequency ablation for patients with Barrett's esophagus at the Beaumont Hospital and were deeply involved in the care of patients with esophageal cancer to the extent that they received NIH support for some of their work. Besides being part of a very busy cardiothoracic surgical group at the Beaumont Hospital, Gary was president of the medical staff, directed their clinical oncology program for thoracic problems, sat on the hospital board of directors, and was a strong contributor to everything at the Beaumont Hospital.

Despite all of these contributions that he and his practice group were making, Gary could not really tolerate seeing the Red Wings beat the Blackhawks or the

Continue page 2

MARCH 2022

Dr. Gary W. Chmielewski, MD, cont.

Tigers beat the White Sox, so that he had to get back to Chicago in order to more closely support his favorite teams. Most of his colleagues thought he was crazy to leave Detroit and go to Rush University in 2010. For the next eight years, Gary was one of the favorite teachers at Rush and continued to expand his horizons as a thoracic surgeon by expanding minimally invasive thoroscopic procedures and becoming deeply involved in thoracic robotic surgery. Part of his growth in this area related to becoming involved with Dr. James Luketich, who is one of the giants in thoracic surgery.

During these eight years at Rush, his practice grew as did his technical procedures in robotic surgery. Following this very productive period at Rush, Gary decided to accept the position of Chief of Thoracic Surgery at Advocate Aurora Health in Park Ridge. This is the flagship hospital for his medical corporation. He has expanded his experience with thoracic robotic surgery as it relates to lung cancer, and many other challenging problems are referred in to him from the Chicago area. He has two partners, Dr. Axel Joob from the University of Michigan and his thoracic PA, Dr. Hector Martinez, who has been with him now for over ten years. He will be bringing on a new partner, Dr. Alex Cedano Rodriguez, who will be coming to Chicago from Albany.

The following are Dr. Chmielewski's updates on his family and free time over the past 15 years.

FAMILY

The most important thing in my life is that my lovely bride, Monica, and I celebrated our 16th wedding anniversary last November. As you recall, she is an attorney and a force to be dealt with. She has had such a positive influence on me and the kids — all our lives are so much better because she is the matriarch of our family. She has an extreme love for everything Disney - hence our purchase of a second home in Celebration, Florida, ten minutes from the Magic Kingdom. We all have enjoyed time together there with family and friends and I recently celebrated my 60th birthday in Celebration, Florida.



Gary and Monica celebrating 16 years



The Chmielewski Clan celebrating Sarah and Michael's Marriage

The twins (now 27) and triplets (now 25) are all launched. Andrew is an airline pilot for SkyWest and will soon be moving up to one of the major carriers. Sarah graduated from Kent State podiatry school and is now doing her podiatric surgical residency at the DMC! Imagine that, another Chmielewski at Detroit Receiving. She also married Michael Messina this past summer who is a high school teacher and coach in Troy and a great addition to our family.

Before Covid hit, we managed to take the triplets to Italy, France, and Spain for a birthday present. Matthew is a 2nd year medical student at MSU (White coat ceremony pictures below), Daniel is working as an ER tech at the University of Chicago after graduating from Loyola - he is applying to medical school this year, and Rebecca is at Kent Law School in Chicago.

Continue page 3

MARCH 2022

Dr. Gary W. Chmielewski, MD, cont.

FREE TIME

I have been able to pursue my three passions over the years: Painting, Flying, and Golf.

Art is something I have done since early childhood. I draw and paint in watercolors and oils. I just moved my art studio from the west side of Chicago to Florida. I have included a picture of an oil painting I did of Rush University Medical Center.

I obtained my private pilots license my last year of medical school at Loyola - the day I passed my check ride, I left in a moving van to Detroit and WSU to start my surgical residency. It only took me 23 years to get back to Chicago. Since that time, I have amassed nearly 1000 hours of flight time, added an instrument rating, and I am currently working on my commercial pilot certificate. I have flown a cirrus SR22 all over the USA, but my favorite trip is taking my dog Hogan back and forth from Florida.


I have a close group of guy friends I have travelled all over the world to play golf with. Two of the pictures included are from Pinehurst, North Carolina, and St. Andrews in Scotland.

I have a great life and if I checked out tomorrow, I have no regrets. I think it is important for the young surgery residents to know that they are getting great training at Wayne State University to start their careers and to be flexible in developing a variety of skill sets over time that will lead to much career fulfilment. They need to know that they may be working hard, but their family and friends are sacrificing a lot so they can follow this career path in surgery. Make sure to thank them for their support every chance they get. One final thing, "honor your passions", it makes life worth living.

Gary Chmielewski



Gary in his art studio



Hogan enjoying the flight



Dr. Chmielewski with Cirrus



Monica Chmielewski at Disney



Dr. Chmielewski's painting of RUMC

MARCH 2022

Dr. Gary W. Chmielewski, MD, cont.



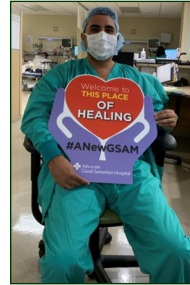
Dr. Chmielewski at St. Andrews



Dr./ Chmielewski at Pinehurst



Dr. Chmielewski with his partner, Dr. Axel Joob on Doctors Day



Dr. Hector Martinez, the best thoracic PA



Dr. Chmielewski speaking at the GTSC



Dr. Chmielewski's 60th Birthday celebration




Gary & Monica celebrate their son, Matt's, MSU White Coat Ceremony



Gary with his daughter, Sarah on her wedding day




The Chmielewski triplets, Dan, Matt, Bec, in Italy



Dr. Chmielewski's son, Andrew, at SkyWest



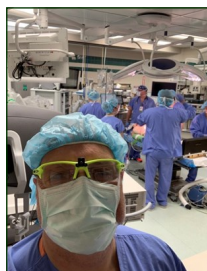Dr. Chmielewski, with his daughter, Sarah, in the DMC tunnels 26 years later



Gary's daughter, Sarah, at the DMC



Dr. Chmielewski, his son, Andrew, and Hogan in flight to Florida



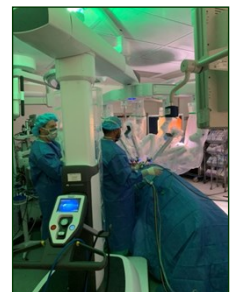
Dr. Chmielewski with his robot team



Dr. Chmielewski (left) with thoracic surgery giant, Dr. James Luketich (center)



Dr. Chmielewski and his team at



The Robot OR at Advocate



MARCH 2022

Dr. Linda Phillips: Wayne State Surgical Star

Dr. Linda Phillips was born and raised in Chicago and matriculated at the University of Chicago, where she attained her Bachelor's degree in Linguistics, after which she graduated from the University of Chicago Medical School in 1978. She continued her training at the University of Chicago, where she did her basic surgery training when the famed Dr. David Skinner was chairman, after which she completed her General Surgery training at Northwestern University in 1983. She returned to the University of Chicago for her plastic surgical training, which she finished in 1984, after which she moved to Detroit and began her career in the Plastic Surgery division at Wayne State University.



Dr. Linda Phillips

The Plastic Surgery Service at WSU was very productive at that time and had a number of surgical scientists, including Dr. Martin Robson, Dr. David J. Smith, Jr, and Dr. Linda Phillips. Dr. Phillips spent five years at WSU and was actively involved in all of the Detroit Medical Center hospitals and the Veterans Administration Hospital. Besides being involved actively in reconstructive surgery, she was the director of the Detroit Receiving Hospital Burn Center in the mid-eighties. During these five years, Dr. Phillips and her teammate published over 20 peer-reviewed abstracts that dealt with multiple topics, including the role of Biobrane in treating burn injury, layered closure of complicated reconstructive lacerations, the use of biosynthetic compound dressings for complicated hand burns, the effect of endogenous skin bacteria on burn wounds, the treatment of facial fracture, and many other topics.

After her tenure at Wayne State, Dr. Phillips, along with Dr. Robson, moved to the University of Texas Medical Branch in Galveston. She rapidly became actively involved at the Shriners Hospital for Children in Galveston and, in 1993, became the Co-Chief of the Division of Plastic Surgery at UT. Since 1994, she has been the Truman Blocker Distinguished Professor at UT and the Chief of the Division of Plastic Surgery. She continues to serve in these positions and is also the Director of the Plastic Surgery Residency Program at UT. Her administrative skills were recognized by the medical school administration with the result that she has served as the Senior Associate Dean for Academic Affairs from 2001 thru 2013 and served as the Vice-Chair of the Department of Surgery Clinical Operations thru 2016. Currently, she is the Director of the Academy of Master Clinicians at UT.

Continue page 6



MARCH 2022

Dr. Linda Phillips: Wayne State Surgical Star, cont..

Dr. Phillips has been involved in many research projects, which have received external support. Her particular interests include jet lavage and antibiotics for contaminated wounds, the impact of infection on metalloproteases, management of an ischemic flap model, breast reconstruction and reduction, management of complicated pressure sores, and many others. Her research has received external funding for over 30 of her projects over the years, dating back for more than 25 years.

Dr. Phillips has been involved in extramural activities to an extensive degree. She is a member of all the plastic surgical societies and has served on multiple committees within these societies. Likewise, she has often been an officer at all levels, serving as vice-president of many national organizations. She has served in all positions for the Wound Healing Society. Her many contributions nationally to plastic surgical associations are too numerous to incorporate into this report. These many administrative contributions are local, regional, national, and international.

Dr. Phillips is certainly a surgical scientist, having published well over 100 peer-reviewed publications and 50 book chapters related to her specialty. She is also frequently in demand to give lectures and has presented over 200 invited lectures, both regionally and nationally.

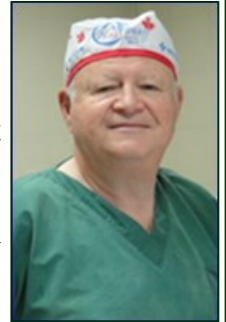The American College of Surgeons (ACS) is the most important surgical association in the world. The ACS has representatives from all of the states and territories and many other countries who send representatives as members of the ACS Board of Governors. The hundreds of members of the Board of Governors discuss multiple issues and then forward these discussions up to the small Board of Regents, who are actually the individuals who run the ACS and choose the officers, including the director of the ACS. Dr. Phillips has been a member of this select Board of Regents since 2015 and is currently serving at the vice-chairperson of the ACS Board of Regents. Later this year, the ACS will again have their annual meeting live (not virtual), and this meeting will take place in San Diego in October. Be sure to attend the Opening Ceremony and see Dr. Phillips on the stage with the other Regents during the Opening Ceremony.



MARCH 2022

Dr. Melvyn Westreich: Memories Of A Special Mortality and Morbidity Conference

Dr. Melvyn Westreich (WSU/GS 1970/75) was an excellent surgical resident, who became a leading academic surgeon in Israel. He has many publications and had a very busy practice prior to his retirement. Now he is an excellent novelist and writes mysteries, usually related to his experiences in Michigan. Everything he relates about this following event is true. I was sitting just behind Dr. Alec Walt. None of the residents gave it away!



Dr. Melvyn Westreich

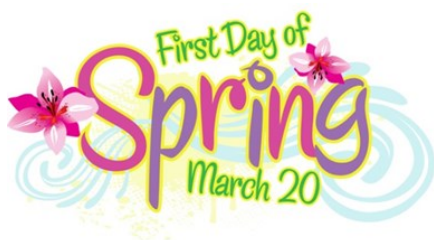Dear Dr. Lucas,

Thank you for putting out the email report every month. It certainly brings back memories. I especially like Dr. Ledgerwood's log book.....I can visualize each and every surgeon at work.

I write to you now, to remind you that it is now 47 years since that "special" Mortality and Morbidity Conference (1975). I sent you a copy of the article that I published in the 'Journal of Irreproducible Results' about that conference. I don't know if that conference was an important milestone in the history of our surgery department, but it was memorable. I am not getting any younger and I do not have your energy, but I thought perhaps the time has come to remind the younger generation of surgeons about this part of the WSU surgical legacy(?). Below is my article for your consideration for possible inclusion in the monthly email report. Stay Healthy.

Mel

P.S. I asked the editor of the Journal of Irreproducible Results for permission to republish, and it was granted, but there should be a citation that it was published first in their journal.



Continue page 8

MARCH 2022

Dr. Melvyn Westreich: Memories Of A Special Mortality and Morbidity Conference, cont...

West Pole · Chem Class · Quickies p32

The Journal of Irreproducible Results®

The Science Humor Magazine ;-)

Mosquito/Bird Hybrid Page 12



\$5.95
 Volume 50,
 Number 3
 2007
www.jir.com
 ISSN 0022-2038



The Patient Who Had Everything
 Cold Reading · $(EI)^2O$ · Limericks
 Shakespeare in the Original Klingon

JIR guarantees this issue against damage or destruction by chupacabras or sasquatches. Claims for replacements must be supported by appropriate court judgements, or stories or illustrations funny enough to publish.

The following article was first published in the Journal of Irreproducible Results Volume 50:3; 2007.

Continue page 9



MARCH 2022

Dr. Melvyn Westreich: Memories Of A Special Mortality and Morbidity Conference, cont...

My Last Mortality and Morbidity Conference, 1975

Melvyn Westreich, MD, School of Medicine, Tel-Aviv University

Mortality and Morbidity (M&M) Conferences in the Surgery Department at Wayne State University were a cross between a serious academic effort in educating the resident staff, and feeding time for the lions at the Coliseum in ancient Rome. The conference was held every Friday afternoon in the fourth-floor auditorium of the old Detroit General Hospital.

The room was a large narrow hall with 2 entrance doors along one long side. The room had about 150 chairs oriented to the rostrum in the middle of the room between the 2 doors. The center seats were reserved for the heads of the divisions and the senior-most attendings. The center-most seat was for the Chief, Prof. Alexander J. Walt, affectionately called the "old man" by us all, even though he was only in his early 50s. The rest of the auditorium was filled with junior staff, residents, and medical students.

Cases were always presented by the resident staff but the attending staff were equally on trial. Just the thought of having to stand before this tribunal was enough to keep every resident on his toes and watching that none of his patients had any unexpected complications. During the official presentation no one would speak except to ask for a clarification of something in the protocol. When the resident finished, one of the front row inquisitors would chant the litany of, "Why did this happen to your patient?" and the tribunal would begin. Any resident who presented a case was sure to have spent the previous night in the library researching the literature on every complication, problem, and mishap that had befallen his patient. Woe to the resident whose knowledge was lacking.

In an operating room lull, during my last month of general surgery residency at Wayne State University, a plot was hatched between Dr. JK and myself. Dr. JK was then a younger member of the senior staff and while Dr. YS was away on a sabbatical, he was temporarily in charge of the mortality-morbidity conference of the department. We thought that the last M&M conference of the year, and of my surgical residency, should be one to remember. I suggested it would be highly educational to go over the variety of complications I had seen in my years as a student and resident at Wayne

State. Dr. JK liked the idea and agreed that at the last conference of the academic year, I was to present a fictitious case that would contain a collection of these complications.

Dr. JK also suggested, and I agreed, that it would be more "interesting" if I did not indicate in any way that the case was anything but real. He wanted to see how long it would take the other surgeons to realize that no such patient actually existed. He stipulated that the case must be the last on the conference protocol, and that it be printed on a separate sheet, so that the case report could be expunged from the official records of this important university conference after the presentation.

I wrote up the case report and presented it to the department secretary at the beginning of the week, along with Dr. JK's instructions that it be last and on a separate sheet.

On the afternoon of the conference I was shocked to discover there were only 2 patients on the protocol, and my "patient" was the first. I rushed down to the secretary who explained that when I handed in my report it had been the only case report, and that the second only came in at the last moment. This was in the days of stencils and mimeo machines, and she did not want to do the whole thing again just so that it would move to the end.

I went up to the conference hall to explain things to Dr. JK. However, when I got to the auditorium I discovered that Dr. JK was nowhere to be seen, and Dr. YS, newly returned from his sabbatical, was chairing the conference as usual. The protocol of the conference had been circulated and everyone was settling down for the start of the conference. Dr. YS asked me to begin my presentation.

I quickly took him aside to inform him that my case was a joke presentation concerning a fictitious patient, and that the entire idea had been arranged with Dr. JK. With a certain gleam in his eye, Dr. YS, known for his bon-vivant way of doing things, informed me that M&M conference was a serious part of the academic activities of the department, and he could not condone any levity. However since he had no prior knowledge of this patient, and since it was the first on the protocol, he demanded I begin.

JIR 18

Continue page 10



MARCH 2022

Dr. Melvyn Westreich: Memories Of A Special Mortality and Morbidity Conference, cont...

All the full professors, including the chairman, had reached their places in the front rows. The auditorium was now filled with house staff and students. With great trepidation and a sinking feeling in my heart I rose to the rostrum and began my narrative.

Protocol

**5-6-75 3:00 PM Patient is a 62 year old presented in ER with history of falling, and suggestion of ruptured spleen.
XRAYS: Fx. left 9th rib.**

Narrative

On the sixth of May, 1975, Mr. J.W. came to the emergency room requesting an appointment to the ophthalmology clinic. The week before he had fallen at home and broken his glasses. He wanted the appointment to get a prescription to replace his spectacles. The conscientious intern on duty, using a problem-oriented approach, duly noted the patient's remark that he had "blacked out", and began working up the patient for his falling episode. He noted that the patient had tenderness in the area over his left ribs. The intern ordered blood work and rib XRays that showed a healing fracture of the left ninth rib. The intern could not tell if the tenderness was only from the fractured rib, and was concerned whether there was an underlying ruptured spleen. A consultation from the surgery resident was requested.

So far pretty straight forward.

6:00 PM Left chest tube placed.

The surgery resident examined the patient but could not completely rule out a delayed rupture of the spleen, and felt that he could be sure only after performing a diagnostic peritoneal lavage. Before the DPL was performed the resident felt it only prudent, for safety's sake, that the patient have an intravenous line. Since Mr. J.W. was so thin, and since he was so cooperative and because the gaggle of medical students had never seen a subclavian catheterization, the resident decided to begin a subclavian IV.

The resident slid the needle in with a flourish, expecting to hear the oohs and aahs of the impressionable students, but all he heard was the patient suddenly gasp for breath. He

removed the needle and a quick XRay confirmed the left sided pneumothorax.

The students had the additional treat of witnessing a chest tube insertion.

The plot thickens.

7:00 PM Right chest tube placed.

It was standard procedure for the department that all patients with chest tubes get IV Penicillin for as long as the tube was in place. There was a sub-cutaneous hematoma at the site of the attempted left subclavian catheterization, so the resident decided that he would start a right subclavian IV. On insertion of the needle on the right, the patient again began gasping for breath, and XRay at this time showed a right pneumothorax. A right sided chest tube was placed.

7:15 PM Cardiac arrest. - 20% burn of chest.

Standard treatment for patients with chest tubes was prophylactic antibiotics. With the second tube in place, the patient was questioned whether he was allergic to penicillin. He related that he could not recall any such allergy, but also could not remember if he ever took penicillin or any antibiotic in his life. An initial bolus of IV Penicillin was injected, and the patient related that, "it must be good stuff", since he could definitely feel it going around his body. In rapid succession purple blotches developed on his arms and legs, he became short of breath, and his eyes rolled up in their sockets. His blood pressure was undetectable, and he went into cardiac arrest. He was taken into the resuscitation room, intubated, and closed cardiac massage with resuscitative drugs were begun. The monitor showed ventricular fibrillation, and the defibrillator was prepared. Conductive gel was in short supply in the ER, and alcohol-soaked sponges were placed on the patient's chest to improve conductivity. With the first electric shock the patient converted to NSR, but the spark from the shock also ignited the sponges and the alcohol that had dripped down the sides of his chest and abdomen, causing second and third degree burns.

At the best of times standing in front of the M&M conference was not a pleasant experience. Even if your patient had a completely unavoidable complication, and you had done everything possible to correct

JIR 19

Continue page 11

MARCH 2022

Dr. Melvyn Westreich: Memories Of A Special Mortality and Morbidity Conference, cont...

the problem, it was still frightening. The staff were inclined to rake you over the coals. Picture, if you will, those front rows, with the senior staff fidgeting in their seats, just waiting for me to finish my presentation. I do not remember anyone actually drooling, but in that atmosphere it would have been appropriate.

7:20 PM Tracheostomy - Taken to OR.

Drugs were now administered to treat the anaphylactic reaction to the penicillin. The patient remained unconscious, and it was decided to perform the peritoneal lavage to rule out the splenic rupture. A large needle was inserted into the epigastric area through the linea alba. On aspiration there was immediate return of fecal material in the barrel of the syringe. It was decided to take the patient for exploratory laparotomy to rule out the suspected visceral injury. The patient remained unconscious since his cardiac arrest, and it was felt that the patient would probably require long-term ventilatory support and would need a pre-operative tracheostomy that was done in the ER. He was then taken to the OR.

The air in the auditorium was now charged with electricity. The senior staff seemed to read the protocol with undeniable joy. The closest way to describe the atmosphere in the room would be to envision a pack of circling sharks smelling the blood of the victim, and waiting for the sign to begin the feeding frenzy.

8:45 PM Foley passed by GU because of GC in past.

In the operating room, multiple attempts at passage of a Foley catheter were unsuccessful due to urethral stricture probably because of old gonorrhea. The urology resident was called, and using stents and fine catheters, the resident was able to thread a catheter into the pelvis. When the catheter was attached to dependent drainage there was only bloody return. It could not be determined where the catheter was actually situated but it was assumed that a false passage had been created. The patient had urinated during his resuscitation and the bladder was not palpable. It was decided to insert a supra-pubic tube once the abdomen was opened.

It gets better and better.

9:00 PM Expl. lap.- Colostomy, SP tube, splenectomy.

The laparotomy incision was made through the burn area in the midline. There was a tear of the anterior wall of the transverse colon from the DPL needle, with fecal spillage. At exploration of the abdomen the spleen was found to be intact, but because of slightly aggressive handling by the junior resident, who also wished to palpate the spleen, the capsule ruptured, so a splenectomy was performed. A supra-pubic tube was placed, and a loop colostomy of the injured colon was exteriorized to the skin of the lower, unburned, abdomen. The abdomen was closed in layers. Through and through tension sutures over bolsters were placed, and a Penrose drain was brought out separately.

Prof. Walt kept bobbing his head up and down, looking from the rostrum to his protocol. He had this pained non-believing look on his face and grasped the protocol tightly in his hand throughout the narrative.

5-7-75 2:00 AM Returned to OR for drainage of Penrose.

The patient did well for the next few hours but the recovery room nurse noted that there was fecal-like drainage from the Penrose drain. It was decided to take the patient back to the operating room. At surgery it was discovered that the cause for the drainage was from one of the through-and-through tension sutures, that had caught a loop of small bowel. It was draining into the peritoneal cavity and out through the Penrose. The injured area was resected, and anastomosed primarily. The abdomen was closed in layers.

Prof. CL got up at this point and left the room. This was quite unusual for him since he felt that this conference was one of the most important in the academic schedule of the department. He told me afterwards that he figured out that the patient was fictitious, since if such a patient had existed it would have been under his service. He left to avoid bursting out in laughter and spoiling it all. He was enchanted by all the other staff smiling and nodding their heads at the tale of woe of the poor unfortunate patient. Each seemed

JIR 20

Continue page 12

MARCH 2022

Dr. Melvyn Westreich: Memories Of A Special Mortality and Morbidity Conference, cont...

to beam in satisfaction as they sharpened their claws waiting to lay into me once the official presentation was over.

4:00 AM Right chest tube replaced.

After the surgery, when the patient was transferred to the recovery room bed, the tubing of the right chest tube caught on the edge of the gurney. It was then discovered that the sutures that were supposed to fix the tube to the chest had never been tied, and the tube had been held by the adhesive tape alone. The pull on the tubing caused the chest tube to whip out of the patient's chest. The surgery resident responded to the critical situation that faced him. He obtained a new chest tube to replace the one that had been accidentally removed. The tube went in with some effort, and immediately after insertion began to drain pure blood. Stat XRays showed the right tube to be under the diaphragm in the liver parenchyma.

At this point, Prof. IKR, sitting to the left of the "old-man", stopped me to ask in all seriousness, "Dr. Westreich, is this presentation a joke?"

Mustering all my thespian skills I looked him in the eye and said, "Oh no sir, all these things really happened." This was not really a lie, since they had all occurred, just not in the same patient.

He told me to proceed.

The patient was returned to the OR and the abdomen was opened again. The chest tube was removed and replaced in the right chest. Profuse bleeding continued from the liver. The patient received 12 units of blood and 3 FFP. The liver was packed with a gauze tampon to control the bleeding. However, while this pack was in place, the liver continued to bleed, requiring continued transfusion. Whenever an attempt was made to remove the pack, there was profuse bleeding from the cavity in the liver parenchyma. Pringle's maneuver was performed with a large vascular clamp. This slowed the bleeding somewhat but did not stop it. It was decided to perform a right hemi-hepatectomy, to remove the injured tissue and expose the suspected injury to the hepatic veins which was the probable source of the bleeding.

Prof. Walt stopped me at this point. He apparently could not believe that so many horrific things had occurred to a patient under the care of his department. The

following exchange is inscribed in the memories of all who were there that day.

Using his most forceful South African bass voice, Prof. Walt demanded, "Who was the senior staff assigned to the case?"

"Do you mean the name of the staff on the official records?" I asked.

"Yes, I mean just that," he answered sternly.

As if trying to avoid the inevitable I stalled with, "You mean, who is written on the little credit card thingy?"

I looked at him innocently and said, "It was you, sir."

His head flew up as if he had been slammed between the shoulder blades with a 5-pound hammer. The "old man's" neck veins stood out and almost reflexively the old man sputtered one word, "Me?" He seemed to stop breathing for a moment. It was obvious that the shame, and possible litigation surrounding the case, were running through his mind. His face turned a lovely crimson and he looked up at me and said threateningly loudly, "I knew nothing about this case. How did you get this case into the OR without staff present?"

I looked down at him and, belittling the obstacle he had proposed, said "I told the OR crew that you knew we were operating, and you told us to go ahead. We do that all the time."

The "old man" exploded at this point. His intensity of purpose was transmitted by his body language, the menacing glare, the crumpled protocol in his white knuckled fist, and the way his hair seemed to stand on end. He raised his voice and with a vehemence and vitriol I had never known he possessed, slowly said the next few words, "If you think you are being signed out of this program you are very much mistaken."

To understand this comment, realize that this was the end of my residency. As a matter of fact the official start and end day of all residencies was the next Tuesday. I literally had 3 days to go in my residency. I hoped.

Everyone in the auditorium was absolutely silent. Prof. Walt was known for his exceptional aplomb. No one had ever seen him yell or lose his cool. You could hear a pin drop.

MARCH 2022

Dr. Melvyn Westreich: Memories Of A Special Mortality and Morbidity Conference, cont...

During my presentation, Dr. JK, my co-conspirator, finally arrived and slipped in to a seat far to my left. Realizing the delicacy of the situation, he attempted to improve things a bit by saying, "Prof. Walt, I think I can explain. I know about this case ..."

Before he could continue, Prof. Walt cut him off by pointing an accusing finger at him across the room and bellowing incisively, "Then you are equally to blame!"

At this point I did not know if I should laugh or cry. We had successfully fooled the "old man" but I had this funny feeling that maybe he might not find the joke so amusing, and I might not finish my residency. The silence continued a moment more until Prof. IKR added cheerfully, "Dr. Walt, you're not going to stop him now are you? He is going to do a Whipple on this patient in just a little bit. See, it's right here in the protocol."

The "old man" looked into the protocol and after a moment realized that he had been had. He did not exactly smile, but he told me I could go on. A buzz of whispers and chuckles passed around the room replacing the silence of moments before. Smiles appeared on everyone's faces except Prof. Walt, who sank lower in his chair as I continued.

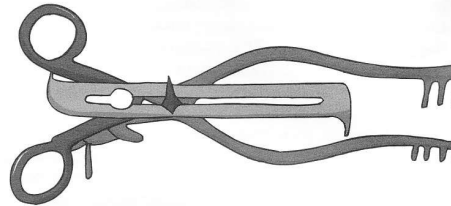
7:00 AM Right Hepatectomy, Whipple procedure, and right chest tube placement.

The hemi-hepatectomy was performed with surprisingly little difficulty, and the laceration of the middle hepatic vein was repaired. However near the end of the procedure it was discovered that the box lock of the vascular clamp had inadvertently been placed so that it crushed the head of the pancreas and the duodenum. This area appeared discolored and unsalvageable, and it was decided to perform a Whipple resection of the injured area.

11:00 AM Patient stable, no drainage, in expensive care unit. Requiring one unit of blood every other day. Extensive WU begun for cause of fall initially. Angio, GTT, EEG, EKG, XRay, scan.

Surprisingly, the patient tolerated the extensive procedures well, but required respiratory support and was taken to the

expensive care unit of the hospital. His vital signs were stable; there was slight drainage from the sump drains in the abdomen. For the first week he required one unit of blood every other day to maintain a hemoglobin of 10. An extensive work-up was begun to determine the cause of his initial "black-out" and fall, including carotid-angiogram, glucose tolerance test, EEG, EKG, Skull XRays, brain scan, etc. All tests were normal. The patient remained stable, and improved from day to day.



5-16-75 Patient extubated. Clarified falling episode, burn granulating well. Wounds healing well. Drains out.

The patient remained in the ICU. He regained consciousness slowly. On May 16, 1975, the patient had his tracheostomy removed and ambulated. He clarified the falling episode and explained that he did not "black-out" when he fell, rather he was "backing-out" of a closet when he tripped on a chair. The full thickness burns on his chest were granulating well, and would soon be ready for a skin graft. All the abdominal drains were removed and the patient was on the regular ward and eating.

5-19-75 Skin graft to burn of chest.

The patient continued to improve from day to day, and it was decided to perform a split thickness skin graft to the burn areas of the chest and abdomen. He was taken to the operating room and under general anesthesia a graft was taken from the left thigh and sutured to the patient's chest.

5-22-75 Skin graft to donor site on thigh.

The patient complained of marked pain in the area of the donor site and subsequent investigation showed that the skin graft from the thigh had been quite thick, and there was now a full thickness defect on the left thigh involving the entire donor area. The donor bed



MARCH 2022

Dr. Melvyn Westreich: Memories Of A Special Mortality and Morbidity Conference, cont...

was quite clean and it was elected to do an immediate skin graft to close the defect. A second graft was taken from the right thigh and was sutured to the left thigh to close the original donor site defect.

5-30-75 Sigmoid, BE, cysto – normal. SP removed.

The grafted areas all healed very well, and a work-up was begun to determine the integrity of the colon and bladder. Sigmoidoscopy, barium enema, and cystoscopy were all normal. The supra-pubic catheter was removed and the patient was able to void spontaneously. The patient was up and about and was not having any difficulty with his colostomy.

6-15-75 Patient up and about. Given (1) Appointment to surgery clinic, (2) Appointment to ophthalmology clinic, (3) Advice.

The patient's strength improved and after 5 weeks was finally discharged home. At his discharge he was given: 1) an appointment to the surgery clinic to have his colostomy closed. 2) the full name of the attending staff doctor responsible for his case, Professor Alexander Jeffrey Walt, MD. 3) The name of one of the more prominent malpractice attorneys in the area. 4) An appointment to the ophthalmology clinic to get the new pair of glasses that had originally brought him to the hospital.

The presentation ended with a round of applause. I am not sure if it was for my creativity in presenting a case with all the varied complications, my phenomenal acting skill in keeping a straight face under fire, or for pulling a fast-one on the "old man". Somehow I have the feeling that the applause was for the last. I still meet some people who were present at that conference and they remember the presentation as one of the highlights of their medical careers. That says something for the highlights of our medical careers.

After the conference, the end-of-the-year commemorative photos of the senior residents were taken in the library. When it was my turn to stand with the "old man" in the official "hand-shake" pose, he smiled, shook my hand and said so that only I

could hear, "About the conference ... I will get you for that."

Was the boss joking? I really do not know. All I do know is that I owe him a great deal for preparing me for my career in surgery. I am sure that the gratitude and respect I had for him is shared by all those that were in the program. I am certainly very proud to have been his resident.

On that very night after the conference, I was the senior resident on the emergency surgery service and Prof. Walt was the staff attending for the night. We operated together amicably through the night. The last case, early the next morning, and the last of my residency, was a gentleman with a stab wound of the heart. This was a fairly common injury thanks to the efforts of the Urban Branch of the Detroit Knife and Gun club. I suggested that the fourth year resident do the procedure, since I had done a good number of these cases and he was to be a senior resident in 3 days. Dr. Walt examined the patient and told me to go ahead with the surgery and that I should supervise the fourth-year resident. He said that he was available if I needed his assistance and that he was sure I would "do just fine".

Postscript

I corresponded with Prof. Walt fairly regularly and he visited me here in Israel. We reminisced about "the" conference in a friendly manner, and he granted me permission to put the embarrassing episode to paper and even approved the preliminary manuscript. He said it gave him a chuckle during his illness. Even when he was sick, his schedule continued to astound me and I cannot believe how busy he kept himself. During his term as president of the American College of Surgeons, I know he did for the college what he did for all of us. He guided, chided, challenged, and supported so that tomorrow's surgeons would be able to "do just fine". I have not stopped thanking him. I miss him greatly. Looking back on that day, with the perspective of having my own department and residents to guide, I ask myself if I would I do it all over again. Would I once again attempt to fool the "old man" in that nasty way? Yes, I guess I probably would. I just hope my residents never do it to me.

MARCH 2022



REPORTS FROM THE OUTFIELD



PRODUCTIVITY

Nearly all of our residents (and PD and APD who snuck in the back) took the ABSITE Exam the weekend of January 29 and 30, 2022. As always, there was a calm and jovial atmosphere amongst the residents!





MARCH 2022



Warrior Medicine
Urban Clinical Excellence

PEERS RANK DEPARTMENT OF SURGERY'S ACADEMIC ACHIEVEMENT IN TOP HALF OF NATION'S PROGRAMS

An impartial group of academic surgeons have ranked the Wayne State University School of Medicine's Michael and Marian Ilitch Department of Surgery residency program in the top half of academic programs in the country.

The department ranked No. 48 out of 106 departments in a report published in the Journal of Surgical Education.

For ["Ranking United States University-Based General Surgery Programs on the Academic Achievements of Surgery Department Faculty,"](#) the group looked at online data about research funding, the Hirsch index, which measures the impact of particular authors, and participation on the editorial boards of major surgical journals.



Dr. Donald Weaver, MD

"This was different from some rankings that weigh value by polling surgical leaders concerning their opinion about programs," said Penberthy Professor and Chair Donald Weaver, M.D. (WSUGS 1979) "Compared to many universities, our department is rather small and without its own hospital system, so to be in the upper half of the academic programs is a testament to the fine work of our dedicated faculty, and the residents and students who challenge us daily to excel."

The programs were selected from the American Medical Association Residency & Fellowship Programs Database. The study evaluated university-based general surgery residency programs in the United States from 2017 to 2019, assessing their respective institutions' departments of surgery. A total of 7,568 faculty members were evaluated. Faculty were required to be full-time clinical surgeons to meet inclusion criteria.

The Michael and Marian Ilitch Department of Surgery has a long and proud history of service, education, and research. It is home to more than 70 residents and fellows, taught by 47 full-time faculty and more than 90 clinical faculty.

"Students who choose our program for residency training should be confident that it stands on a solid academic footing. The department is always striving to improve, but it has much to be proud of," Dr. Weaver added.



"EXCERPTS FROM LOG BOOK" - DOWN MEMORY LANE

Anna M. Ledgerwood, MD

1/17/71: Staff, Dr. Birks; chief resident, John Watts

1. LR: 70-year-old female with history of ulcers for the past two years; large, perforated, prepyloric gastric ulcer—1.5 x 1.5 cm—and posterior penetrating duodenal ulcer. Treated with antrectomy, vagotomy, and gastrojejunostomy.



Dr. Anna Ledgerwood

1/18/71: Staff, Dr. Jackson

1. DD: Massive obesity (greater than 400 pounds) with GSW abdomen and had negative exploratory lap and tracheostomy. Developed respiratory distress, had revision of tracheostomy with marsupialization of stoma to skin.
2. AJ: GSW abdomen. Negative exploratory lap.
3. VG: 87-year-old male with large perforated gastric ulcer in the body of the stomach on the lesser curvature. Appeared to be old perforation with massive purulent peritonitis. Treated with exploratory lap, biopsy, omental patch, and closure of the perforated ulcer.

1/19/71: Staff, Dr. Eisenstein

1. WH: Blunt trauma (kicked in abdomen) 24 hours PTA. Found to have free air under the diaphragm. At laparotomy, had perforation of proximal jejunum 3 feet from Treitz and treated with repair of perforation.
2. JB: Driver in MVC with fracture of ribs 5 to 7 and flail segment and fracture of maxilla with abdominal pain. Laparotomy showed tear of the right lobe of the liver with hematoma. Treated with evacuation, Penrose drainage, tracheostomy, and placed on a volume ventilator.
3. WT: Abdominal pain times one week with rigid abdomen and air fluid levels in small bowel. Treated with laparotomy with findings of gangrenous bowel with massive peritonitis and gangrene from ileocecal valve for 3 feet of distal ileum. Treated for resection of gangrenous bowel and right colon with ileostomy, mucus fistula, and tracheostomy. ("Worst case of dead bowel I have ever seen—several days old—small bowel too edematous for anastomosis.")

1/20/71: Staff, Dr. Kambouris

1. SK: GSW abdomen and chest with fractured spleen and perforations diaphragm times six with left hemopneumothorax and laceration left lobe of liver. Treated with splenectomy, repair perforated diaphragm, debridement left lobe of liver, placement of left chest tube, and debridement of the entrance wound.

Continue page 18



DOWN MEMORY LANE — Anna M. Ledgerwood, MD

2. AS: GSW sternum and left chest with left hemopneumothorax and hematoma mediastinum. Underwent “Ravitch flap” with exploration of the mediastinum and great vessels and ligation of laceration of the jugular vein and placement left chest tube.
3. SP: GSW abdomen with perforation transverse colon times two and jejunum times four and through-and-through right lobe of the liver. Treated with oversewing of colon wound, resection of small bowel with anastomosis and Penrose drainage of liver injury.
4. WP: Assault and beaten with fractured ribs left 3 to 8 with flail chest and pneumothorax. Treated with tracheostomy for Valium ventilator and left chest tube.

1/21/71: Dr. C. Burnys

1. PR: MVC with multiple left rib fractures and left hemopneumothorax. Arrested in ED. Left chest opened and spleen in chest. Taken to OR where aorta cross-clamped. Patient expired in OR. There was a ruptured diaphragm and fracture of the spleen.
2. PL: Stab abdomen, which was penetrating, with negative exploratory laparotomy.
3. TH: GSW right thigh. Exploration was negative.
4. SN: GSW thigh and calf across the popliteal space. Had laceration of the popliteal vein. Treated with ligation and fasciotomy.

1/22/71: Staff, Dr. Lenaghan

1. LS: GSW abdomen with multiple perforations of the ileum. Treated with resection and anastomosis. Perforation of urinary bladder. Treated with repair and suprapubic cystostomy tube.
2. RB: GSW left chest at second intercostal space, anterior axillary line with bullet in the right back, and bilateral hemopneumothorax with hematemesis. Taken to OR urgently with bilateral thoracotomy through third intercostal space and across the sternum. Heart was empty without obvious evidence of blood loss on immediately opening the chest. Patient expired in OR, although BP was 180 systolic prior to opening chest. (“In retrospect, had a little problem with hemorrhage and airway on opening mediastinum. This appeared to be aorto-esophageal fistula. Put clamp on aorta below the left subclavian. Trachea was almost transected just above the carina. Don’t know what else to do except place endotracheal tube in mainstem bronchi on either side.”)

1/23/71: Staff, Dr. LeBlanc

1. BM: Acute appendicitis. Treated with appendectomy.
2. GSW thigh. Arteriogram showed normal vessels. Exploration of the vessels was normal.
3. TB: GSW abdomen and thigh. Treated with exploratory lap for laceration of the liver. Treated with drainage. Exploration of femoral vessels was negative.
4. HJ: 56-year-old deaf mute with upper GI bleed and hemoglobin 2.7 on admission and active bleeding, which did not clear. Taken to OR. Found to have large gastric ulcer with multiple bleeding superficial gastric erosions in the antrum. Treated with 75% gastrectomy, vagotomy, and Billroth II anastomosis.



MARCH 2022



WSU MONTLY CONFERENCES

2022

Death & Complications Conference
Every Wednesday from 7-8



Didactic Lectures — 8 am
Kresge Auditorium

The weblink for the New WebEx Room:
<https://davidedelman.my.webex.com/meet/dedelman>

Wednesday, March 2

Death & Complications Conference

To Be Determined

Jason D. Wilkinson, PhD, LPC, LLP, CAADC

Wayne State University Department of Psychiatry and Behavioral Neurosciences

Wednesday, March 9

Death & Complications Conference

To Be Determined

John D. Webber, MD, FACS

Wayne State University Michael & Marian Ilitch Department of Surgery

Wednesday, March 16

Death & Complications Conference

“How to Build an Academi Career Focused on Research”

Phillip D. Levy, MD, MPH, FAHA, FACC

Wayne State University - Wayne Health

Wednesday, March 23

Death & Complications Conference

To Be Determined

David Springstead, MD, PGY-5 Surgery Resident

Wayne State University Michael & Marian Ilitch Department of Surgery

Wednesday, March 30

Death & Complications Conference

To Be Determined

Launa Clough, DO, PGY-5 Surgery Resident

Wayne State University Michael & Marian Ilitch Department of Surgery



**Wayne State Surgical Society
2022 Donation**

Name: _____

Address: _____

City/State/Zip: _____

Service Description	Amount
2021 Dues Payment _____ \$200	_____
My contribution for "An Operation A Year for WSU" _____	_____
*Charter Life Member _____ \$1000	_____
Total Paid _____	_____

Payment by Credit Card

Include your credit card information below and mail it or fax it to 313-993-7729.

Credit Card Number: _____

Type: MasterCard Visa Expiration Date: (MM/YY) _____ Code _____

Name as it appears on card: _____

Signature: _____

Billing address of card (if different from above):

Street Address _____

City _____ State _____ Zip Code _____

*I want to commit to becoming a charter life member with payment of \$1000 per year for the next ten (10) years.

Send check made payable to **Wayne State Surgical Society** to:

Charles Lucas, MD
Department of Surgery
Detroit Receiving Hospital, Room 2V
4201 St. Antoine Street
Detroit, Michigan 48201

MARK YOUR CALENDARS

*American Surgical Association 142nd
Annual Meeting
Chicago Marriott Downtown, Magnificent Mile
Chicago, Illinois
April 7-9, 2022*

*WSU Medical Alumni Reunion
Weekend
Detroit, Michigan
May 13-15, 2022*

*Michigan Chapter of the American
College of Surgeons Annual
Meeting
Grand Traverse Resort and Spa
Traverse City, Michigan
May 18-20, 2022*



*Please Update Your
Information*

The WSUSOM Department of Surgery wants to stay in touch. Please email Charles Lucas at clucas@med.wayne.edu to update your contact information.



Missing Emails

Over the years the WSU Department of Surgery has lost touch with many of its alumni. If you know the email, address, or phone number of the following WSU Department of Surgery Residency Program graduates please email us at clucas@med.wayne.edu with their information so that we can get them on the distribution list for the WSU Department of Surgery Alumni Monthly Email Report.

Mohammad Ali (1973)

David B. Allen (1992)

Tayful R. Ayalp (1979)

Juan C. Aletta (1982)

Kuan-Cheng Chen (1976)

Elizabeth Colaiuta (2001)

Fernando I. Colon (1991)

David Davis (1984)

Teoman Demir (1996)

Judy A. Emanuele (1997)

Lawrence J. Goldstein (1993)

David M. Gordon (1993)

Raghuram Gorti (2002)

Karin Haji (1973)

Morteza Hariri (1970)

Harrison, Vincent L. (2009)

Abdul A. Hassan (1971)

Rose L. Jumah (2006)

R. Kambhampati (2003)

Aftab Khan (1973)

Samuel D. Lyons (1988)

Dean R. Marson (1997)

Syed A. Mehmood (2007)

Toby Meltzer (1987)

Roberto Mendez (1997)

Mark D. Morasch (1998)

Daniel J. Olson (1993)

David Packer (1998)

Y. Park (1972)

Bhavik G. Patel (2004)

Ami Raafat (1998)

Kevin Radecki (2001)

Sudarshan R. Reddy (1984)

Renato G. Ruggiero (1994)

Parvid Sadjadi (1971)

Samson P. Samuel (1996)

Knavery D. Scaff (2003)

Steven C. Schueller (1974)

Anand G. Shah (2005)

Anil Shetty (2008)

Chanderdeep Singh (2002)

David G. Tse (1997)

Christopher N. Vashi (2007)

Larry A. Wolk (1984)

Peter Y. Wong (2002)

Shane Yamane (2005)

Chungie Yang (2005)

Hossein A. Yazdy (1970)

Wayne State Surgical Society

The Wayne State Surgical Society (WSSS) was established during the tenure of Dr. Alexander J. Walt as the Chairman of the Department of Surgery. WSSS was designed to create closer contact between the current faculty and residents with the former resident members in order to create a living family of all of the WSU Department of Surgery. The WSSS also supports department activities. Charter/Life Membership in the WSSS is attained by a donation of \$1,000 per year for ten years or \$10,000 prior to ten years. Annual membership is attained by a donation of \$200 per year. WSSS supports a visiting lecturer each fall and co-sponsors the annual reception of the department at the annual meeting of the American College of Surgeons. Dr. Scott Davidson (WSU/GS 1990/96) will pass the baton of presidency to Dr. Larry Narkiewicz (WSU/GS 2004/09) at the WSSS Gathering during the American College of Surgeons meeting in October 2022. Members of the WSSS are listed on the next page. Dr. Davidson continues in the hope that all former residents will become lifetime members of the WSSS and participate in the annual sponsored lectureship and the annual reunion at the American College of Surgeons meeting.



*Members of the Wayne State Surgical Society
Charter Life Members*


Ahn, Dean	Clink, Douglas	Gerrick Stanley	Lucas, Charles E.	Rector, Frederick	vonBerg, Vollrad J. (Deceased)
Albaran, Renato G	Chmielewski, Gary W.	Grifka Thomas J. (Deceased)	Malian, Michael S.	Rose, Alexander	Washington, Bruce C.
Allaben, Robert D. (Deceased)	Colon, Fernando I.	Gutowski, Tomasz D.	Martin, Donald J., Jr.	Rosenberg, Jerry C.	Walt, Alexander (Deceased)
Ames, Elliot L.	Conway, W. Charles	Herman, Mark A.	Maxwell, Nicholas	Sankaran, Surya	Weaver, Donald
Amirkia, Kathryn C.	Davidson, Scott B.	Hinshaw, Keith A.	McGuire, Timothy	Sarin, Susan	Whittle, Thomas J.
Anslow, Richard D.	Dente, Christopher	Holmes, Robert J.	McIntosh, Bruce	Sferra, Joseph	Williams, Mallory
Sntoniolli, Anita L.	Dujon, Jay	Huebl, Herbert C.	Missavage, Anne	Shapiro, Brian	Wills, Hale
Auer, George	Edelman, David A.	Johnson, Jeffrey R.	Montenegro, Carlos E.	Silbergleit, Allen	Wilson, Robert F.
Babel, James B.	Francis, Wesley	Johnson, Pamela D.	Narkiewicz, Lawrence	Smith, Daniel	Wood, Michael H.
Bassett, Joseph	Flynn, Lisa M.	Kovalik, Simon G.	Nicholas, Jeffrey M.	Smith, Randall W.	Zahriya, Karim
Baylor, Alfred	Fromm, Stefan H.	Lange, William (Deceased)	Novakovic, Rachel L.	Stassinopoulos, Jerry	
Bouwman, David	Fromm, David G.	Lau, David	Perrone, Erin	Sullivan, Daniel M.	
Bradley, Jennifer	Galpin, Peter A.	Ledgerwood, Anna M.	Porter, Donald	Sugawa, Choichi	
Crococo, William C.	Gayer, Christopher P.	Lim, John J.	Ramnauth, Subhash	Tuma, Martin	

Members of the Wayne State Surgical Society—2022 Dues

Alpandre, Cristiano V.	Dulchavsky, Scott A.	Joseph, Anthony	McGee, Jessica D.	Siegel, Thomas S.
Asfaw, Ingida	Edwards, Ryan	Kaderabek, Douglas J.	Meade, Peter C.	Spencer, Amy
Bambach, Gregory A.	Fernandez-Gerena, Jose	Klein, Michael D.	Mueller, Michael J.	Taylor, Michael G.
Baylor, Alfred	Gallick, Harold	Kosir, Mary Ann	Noorily, Michael	Tennenberg, Steven
Bucci, Lorenzo	Goltz, Christopher J.	Larson, Sarah	Paley, Daniel S.	Thomas, Gregory A.
Carlin, Arthur	Hamamdjian, Khatch	Liebold, Walt	Phillips, Linda G.	Thoms, Norman W.
Dawson, Konrad L.	Hilu, John	Lopez, Peter	Porterfield, Lee	Vasquez, Julio
Dittinbir, Mark	Holmes, Robert	Malian, Michael S.	Schwarz, Karl W.	Ziegler, Daniel W.
Dolman, Heather	Jeffries, Christopher	Mayuiers, Matt	Shaheen, Kenneth W.	Zoellner, Steven M.



*Operation-A-Year
January 1—December 31, 2022*



The WSU department of Surgery has instituted a new group of alumni who are remembering their training by donating the proceeds of one operation a year to the department. Those who join this new effort will be recognized herein as annual contributors. We hope that all of you will remember the department by donating one operation, regardless of difficulty or reimbursement, to the department to help train your replacements. Please send you donation to the Wayne State Surgical Society in care of Dr. Charles E. Lucas at Detroit Receiving Hospital, 4201 St. Antoine Street (Room 2V), Detroit, MI, 48201.

Albaran, Renato G.	Chmielewski, Gary W.	Gallick, Harold	Huebel, Hubert C.	Malian, Michael	Novakovic, Rachel L.	Smith, Randall W.	Wood, Michael H.
Anslow, Richard D.	Conway, W. Charles	Gayer, Christopher P.	Johnson, Jeffrey R.	Martin, Donald J.	Perrone, Erin	Sugawa, Choichi	
Antoniolli, Anita L.	Davidson, Scott	Gutowski, Tomasz D.	Johnson, Pamela D.	Maxwell, Nicholas	Porter, Donald	Sullivan, Daniel M.	
Anthony, Joseph	Dente, Christopher	Hamamdjian, Khatch	Joseph, Anthony	McGuire, Timothy	Sankaran, Surya	Tuma, Martin	
Bambach, Gregory A.	Dujon, Jay	Herman, Mark A.	Ledgerwood Anna M.	McIntosh, Bruce	Sferra, Joseph	Whittle, Thomas J.	
Bradley, Jennifer	Edelman, David A.	Hinshaw, Keith A.	Lim, John J.	Missavage, Anne	Siegel, Thomas S.	Williams, Mallory	
Crococo, William C.	Francis, Wesley	Holmes, Robert J.	Lopez, Peter	Nicholas, Jeffrey	Silbergleit, Allen	Wills, Hale	

WSU SOM ENDOWMENT

The Wayne State University School of Medicine provides an opportunity for alumni to create endowments in support of their institution and also support the WSSS. For example, if Dr. John Smith wished to create the “Dr. John Smith Endowment Fund”, he could donate \$25,000 to the WSU SOM and those funds would be left untouched but, by their present, help with attracting other donations. The interest at the rate of 4% per year (\$1000) could be directed to the WSSS on an annual basis to help the WSSS continue its commitment to improving the education of surgical residents. Anyone who desires to have this type of named endowment established with the interest of that endowment supporting the WSSS should contact Ms. Lori Robitaille at the WSU SOM> She can be reached by email at lrobitai@med.wayne.edu.